



MD Program

UNIVERSITY OF TORONTO

# Anatomy

## UNIT 2: Head and Neck

### Lab 4

[CLICK TO ENTER](#)

# Lab 4 Exercise Selection

Select an exercise to begin:

## Pre-lab SLMs

4A SLM CRANIAL NERVES

## Lab 4 Exercises

4.1 THE SKULL

4.2 THE FACE AND PAROTID REGION

4.3 THE INFRATEMPORAL FOSSA

4.4 THE FACE AND PAROTID REGION

If you finish any exercise early...

4.5 FIELD TRIP


Review Lab 1

QUIZLANDIA 4

# 4A Introduction to Cranial Nerves

## Objectives:

When you have learned the material presented in this exercise, you will be able to:


- give the name and number of each of the 12 cranial nerves.
- state the general function  of each of the 12 cranial nerves and the deficits caused by a lesion of each.
- group the cranial nerves by function:
  - the three that carry special senses, I, II and VIII
  - the 5 that are primarily voluntary motor, III, IV, VI, XI and XII
  - the 4 that carry parasympathetic preganglionic fibres, III, VII, IX and X
  - the 3 “mixed bag” nerves, VII, IX and X
- describe the relationship between the 4 nerves that carry preganglionic parasympathetic fibres and the branches of the trigeminal nerves that ultimately deliver the postganglionic parasympathetic fibres to the target tissues

As you've learned, **peripheral nerves** that arise from **spinal nerves** to innervate the **body wall and limbs** contain specific functional subtypes of axons. These nerves contain:

- somatic motor axons that innervate skeletal muscle fibres in the body wall and limbs,
- general sensory axons that monitor the body wall and limbs, and
- sympathetic postganglionic axons that innervate vascular smooth muscle, arrector pili muscle and glands.

Spinal nerves that arise from S2, 3 & 4 contain parasympathetic preganglionic fibres, but these fibres do not contribute to the innervation of the body wall and limbs, but exclusively to the innervation of abdominal and pelvic viscera.

In contrast, **cranial nerves** can be **purely motor** or **purely sensory**, or **mixed**. Also, four cranial nerves contain **parasympathetic preganglionic axons destined to innervate smooth muscle and glands of the face, thorax and abdomen**. Furthermore, some cranial nerves provide sensory input from **special sense organs**, providing us with **vision, smell, hearing and balance** senses.

This SLM groups together the cranial nerves according to their function, starting with those that are easier to learn. Like spinal nerves, cranial nerves never cross the midline, but always innervate ipsilateral  targets.






Three nerves are **special sensory**:

**Cranial nerve I**, the **olfactory nerve** ⓘ, conveys information gathered from receptors in the nasal epithelium that respond to odorant molecules in inspired air, which we perceive as smell; a lesion of this nerve causes **anosmia**.


**Cranial nerve II**, the **optic nerve** ⓘ, conveys information gathered from photoreceptors in the retina, which we perceive as vision; its lesion causes **a visual field deficit**.

**Cranial nerve VIII**, the **vestibulocochlear nerve**, conveys information gathered from receptors in the inner ear that monitor i) balance ⓘ, and ii) sound energy which we perceive as hearing ⓘ; lesions can cause **imbalance** and **hearing loss**.



Five nerves are purely\*  **voluntary motor**. They innervate striated muscle.

**Cranial nerves III\*, IV, and VI**, the **oculomotor** , **trochlear**  and **abducens**  **nerves**, control **extraocular eye muscles**, the voluntary muscles that position the eye in the orbit. The abducens nerve **abducts the eye**, the trochlear nerve **depresses the adducted eye**, the oculomotor nerve controls **all other eye mvts.**


A lesion of any one of these nerves causes the affected **eye to be misaligned (strabismus)**, and eye **movements in certain directions to be limited.**

Cranial nerve III, the oculomotor nerve\*, also carries **parasympathetic preganglionic axons** that control a smooth muscle in the eye, the sphincter pupillae; parasympathetic input causes pupillary constriction. In a lesion of the oculomotor nerve, **the pupil is large (mydriasis)** .

**Cranial nerve XI**, the **accessory nerve**, controls the **trapezius (shoulder shrug)** and **sternocleidomastoid (SCM; turning the head to the contralateral side)** muscles; lesion of this nerve weakens or abolishes these movements.

**Cranial nerve XII**, the **hypoglossal nerve** , moves the tongue; a lesion of the hypoglossal nerve paralyzes the ipsilateral tongue ; on attempted protrusion of the tongue, the non-paralyzed side dominates, and pushes the tongue **toward the weakened side.**

That took care of 8 of the 12 cranial nerves, three purely special sensory and five purely\* voluntary motor; not so bad, so far! This leaves only four more nerves to introduce. Here's one more that is largely **general sensory**:

**Cranial nerve V**, the **trigeminal nerve** , is **sensory to the skin of the face**. It consists of the **ophthalmic (V<sub>1</sub>)**, **maxillary (V<sub>2</sub>)** and **mandibular (V<sub>3</sub>)** subdivisions.

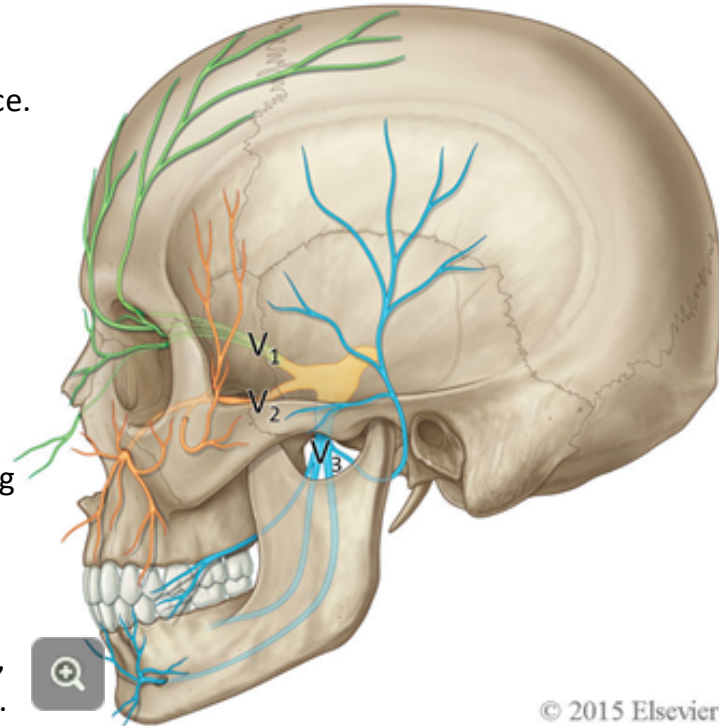
Read the following with reference to the figure.

Branches of the **ophthalmic division, V<sub>1</sub>**, (green) supply general sensory fibres to the forehead, the upper eyelid, the contents of the orbit and the tip of the nose, including portions of the nasal septum.

Branches of the **maxillary division, V<sub>2</sub>**, (orange) supply sensory fibres to the skin of the lower eyelid, the side of the nose, both externally and internally, the upper cheek, the temple, the maxillary teeth, palate, and the upper lip.

Branches of the **mandibular division, V<sub>3</sub>**, (blue) supply sensory fibres to the skin anterior to the ear, over the lower cheek, jaw, mandibular teeth, the floor of the mouth, the lower lip and chin.

The **mandibular division** of the trigeminal nerve is also **motor to the muscles of mastication**. These muscles move the jaw, allowing us to chew. A lesion of these motor branches of V<sub>3</sub> causes weakness in these muscles; **the jaw on attempted protrusion deviates toward the weakened side**.

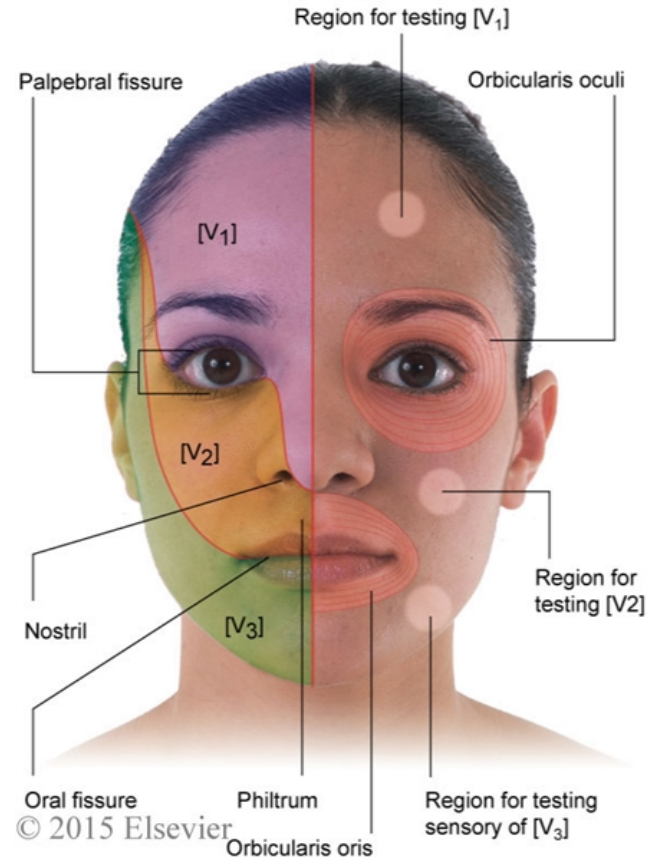


A lesion of a subdivision of the trigeminal nerve causes sensory deficits in a well-defined pattern, as illustrated in the accompanying diagram. In some lesions, the patient might experience a lack of sensation and in others the patient might experience pain. In either case, the distribution of the sensory deficit corresponds to that of a specific trigeminal nerve subdivision or subdivisions, depending on the location of the lesion.




**INFO** **The most reliable places to test for sensory**

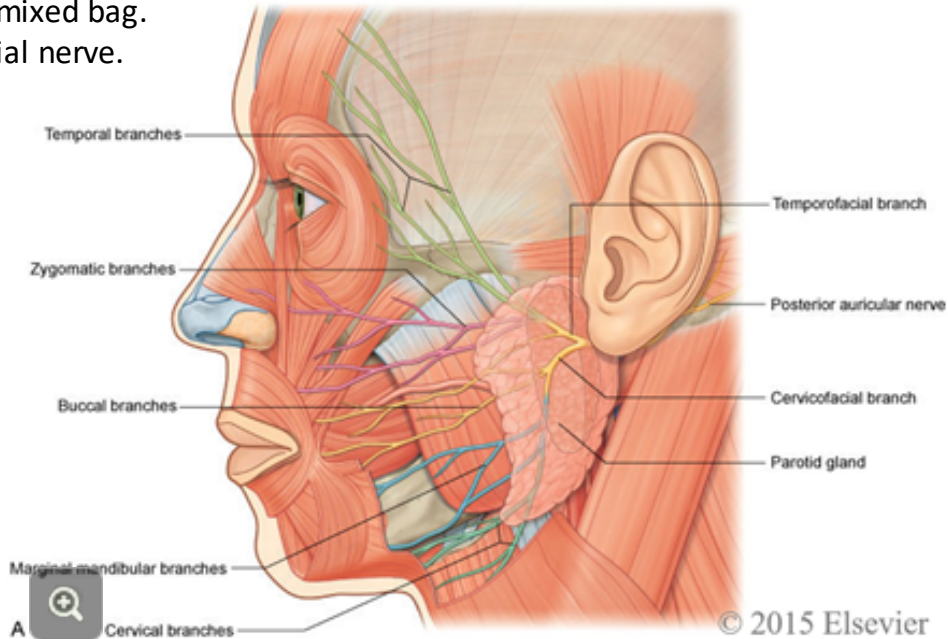
deficits of the trigeminal nerve subdivisions is on the forehead, cheek and jaw, in a vertical line with the eye, as illustrated in the accompanying figure.

Cranial nerves VII, IX and X (see following) have small areas of general sensory responsibility, largely associated with touch to the external ear and ear canal (VII and X) and the pharyngotympanic tube (IX).



This leaves only three cranial nerves to introduce!  
 These are the nerves that are more of a mixed bag.  
 We'll start with cranial nerve VII, the facial nerve.

**Cranial nerve VII, the facial nerve** , controls the **muscles of facial expression**. These are the muscles that allow us to close our eyes and mouth, smile or show our teeth, and raise our eyebrows, for instance . If the facial nerve is lesioned, the ipsilateral face is weakened or paralyzed, and these movements cannot be performed .



The facial nerve also carries **parasympathetic preganglionic fibres** destined to control secretion of the **lacrimal, submandibular and sublingual glands**, as well as the **mucosa of the nasal and oral cavities**.

The facial nerve receives **taste** sensation from the **anterior 2/3 of the tongue**.

Finally, as noted previously, it carries **general sensory** fibres from portions of the **external ear**.

The glossopharyngeal and vagus nerves have much in common. Both carry parasympathetic preganglionic fibres. Both carry voluntary motor fibres. Both carry general sensory fibres. They differ in their distributions.

**Cranial nerve IX**, the **glossopharyngeal nerve** ⓘ, receives **taste** and **general sensory** fibres from the **posterior 1/3 of the tongue**. Its general sensory distribution extends throughout the oropharynx and into the Eustachian (pharyngotympanic) tube.

It also carries **parasympathetic fibres** destined to control secretion of the **parotid gland**.


Its voluntary motor distribution will be described later, when you study the pharynx.

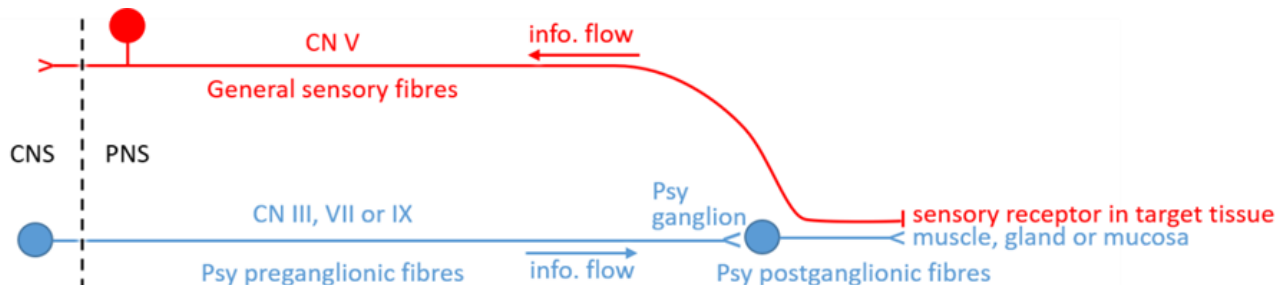
**Cranial nerve X**, the **vagus nerve** ⓘ, carries **parasympathetic fibres** destined to supply thoracic and most of the abdominal viscera.

It is general sensory to portions of the external auditory canal, to the laryngopharynx and larynx.

It is **motor** to the muscles of the **pharynx (swallowing)** and **larynx (speech)**; lesions of the vagus nerve can cause a **hoarse voice** and **dysphagia (difficulty swallowing)**.

Four cranial nerves contain parasympathetic preganglionic fibres in addition to other functional groups of axons, the **oculomotor (CN III)**, **facial (CN VII)**, **glossopharyngeal (CN IX)** and **vagus (CN X)** nerves. Because the targets of the parasympathetic fibres in cranial nerves III, VII, and IX are in the face, we will study them in detail during Unit 2. The targets of the parasympathetic fibres in cranial nerve X are in the thorax and abdomen, so the parasympathetic components of the vagus nerve will be studied in Units 3 & 4.

There is a pattern to parasympathetic outflow. Nerves arising from the central nervous system (CNS) deliver parasympathetic preganglionic outflow to their associated ganglia in the peripheral nervous system (PNS). These ganglia contain parasympathetic postganglionic neuronal cell bodies. Some parasympathetic ganglia, called **terminal ganglia**, are located close to the target tissue. Other parasympathetic ganglia, called **intramural ganglia**, are located in the wall of the target tissue . The parasympathetic **ganglia associated with the oculomotor, facial and glossopharyngeal nerves are terminal ganglia**, and so are **close to, but not in the target tissue**. This means that the postganglionic parasympathetic fibres that arise from these ganglia must travel with another nerve to the target tissue. **In all cases**, the postganglionic axons arising from the terminal ganglia associated with the oculomotor, facial and glossopharyngeal nerves **reach their targets by joining a branch of the trigeminal nerve**.



In **Exercise 4.1**, you will learn the anatomy of the skull. This includes the foramina of the skull and the nerves and vessels that pass through each.

In **Exercise 4.2 / 4.4** you will dissect both sides of the face of cadaver 1. During this dissection you will encounter facial structures and branches of a number of cranial nerves. You will clearly demonstrate:

- the **parotid gland and its duct**, and learn more about the **parasympathetic innervation** of this salivary gland, which arises from cranial nerve **IX, the glossopharyngeal nerve**;
- one of the four **muscles of mastication** and be reminded of its innervation by branches of **V<sub>3</sub>, the mandibular division** of the trigeminal nerve
- **muscles of facial expression** and be reminded of their innervation by branches of **VII, the facial nerve**;
- branches of the **facial nerve**, and of the **facial artery and vein**;
- major branches of the **trigeminal nerve, V**: the **supraorbital nerve** from the **ophthalmic division, V<sub>1</sub>**, the **infraorbital nerve** from the **maxillary division, V<sub>2</sub>**, the **mental nerve** from the **mandibular division, V<sub>3</sub>**.

In **Exercise 4.3** you will study the **infratemporal fossa** using a skull, a model and two prosections. You will clearly demonstrate:

- the borders of the infratemporal fossa and pterygopalatine fossa and the remaining three **muscles of mastication**, located in this region;
- the blood vessels of this region, which are branches of the external carotid artery;
- nerves in this region, including branches of the mandibular division of the trigeminal nerve and of cranial nerves VII, the facial nerve and IX the glossopharyngeal nerve, which deliver parasympathetics to the salivary glands and the mucosa of the floor of the mouth



# 4.1 The Skull

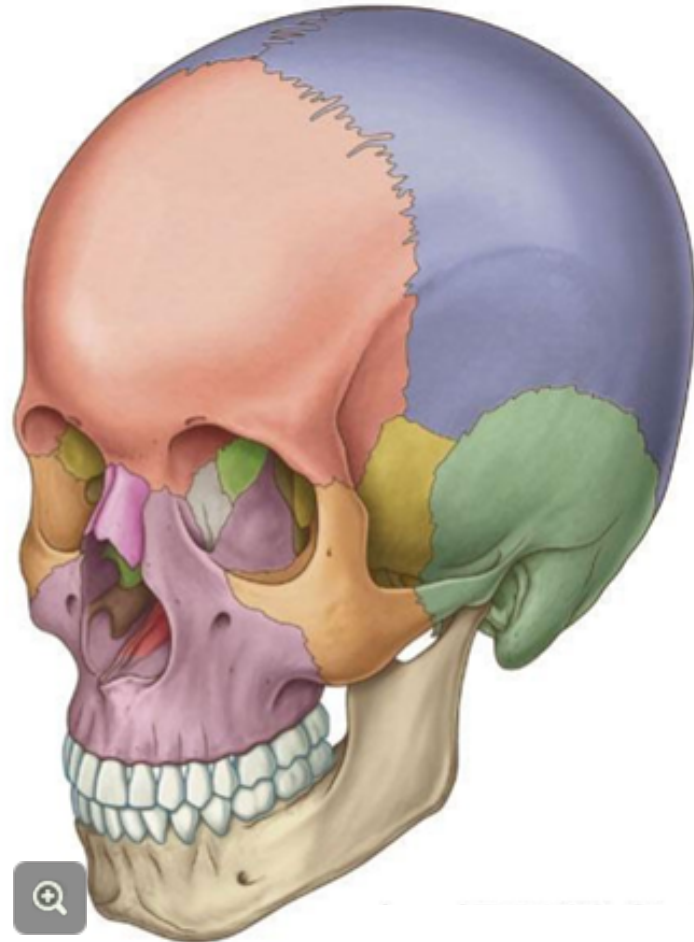What you'll need:

## RESOURCES

- a skull

When you finish this station, you should be able to identify and describe the following:

1. the bones of the skull, including its two subdivisions, the neurocranium (braincase) and the viscerocranium (facial skeleton)
2. the major features and foramina of these bones, as outlined in the pages that follow
3. the structures that pass through these foramina, as outlined in the pages that follow
4. the articulations that join these bones



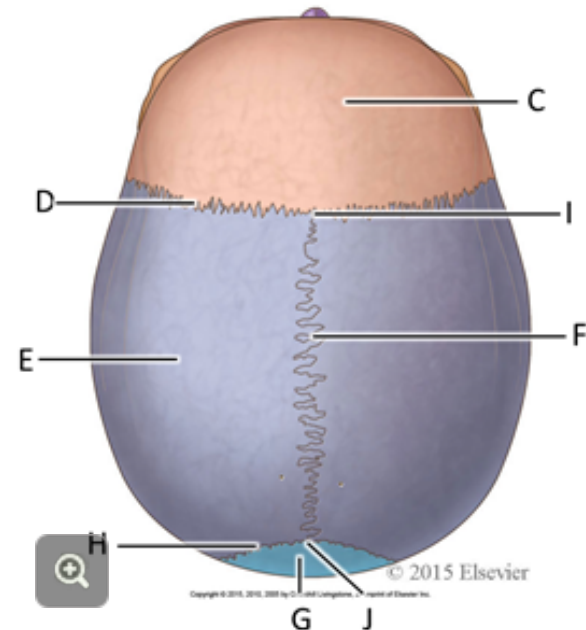
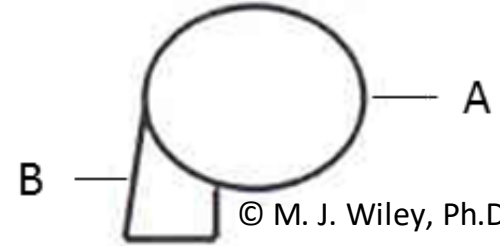
The skull consists of 2 principal divisions; the **neurocranium** or **braincase** (A), and the **viscerocranium** or **facial skeleton** (B).

In the adult skull, the bones of the neurocranium articulate with each other at **sutures** (i); sinuous points of contact where the bones are joined tightly to each other by fibrous tissue, the sutural ligaments.

**TASK** **OBSERVE** the following on the skull provided :

The **frontal bone** (C) is connected via the **coronal suture** (D) to the **parietal bones** (E). The parietal bones articulate with each other at the **sagittal suture** (F) and posteriorly with the **occipital bone** (G) at the **lambdoid suture** (H). The point of intersection, where the coronal and sagittal sutures meet is called the **bregma** (I), and that where the sagittal and lambdoid sutures meet, the **lambda** (J).

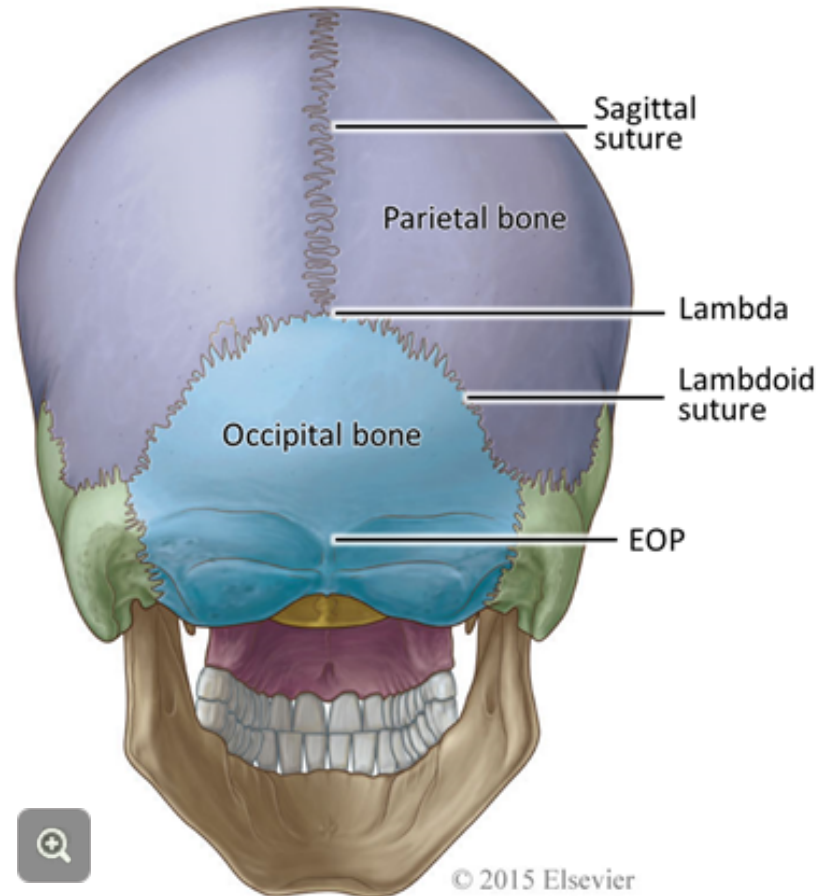
The Skull, lateral view.



T  
A  
S  
K

**OBSERVE** the following on the skull provided:

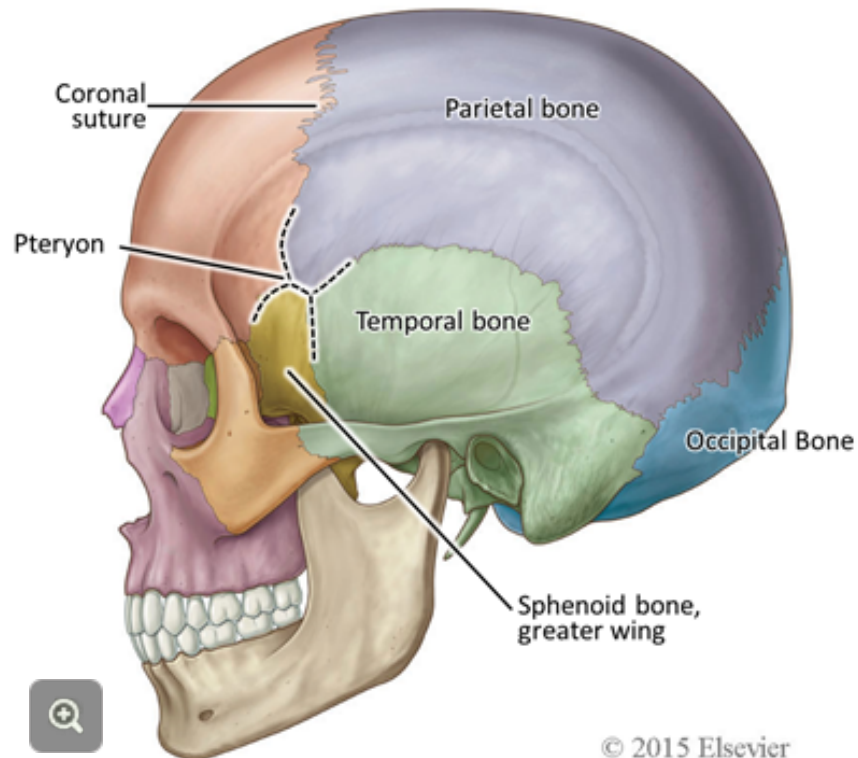
The occipital bone makes up the posterior part of the neurocranium. Identify the **external occipital protuberance** (EOP) on the skull and locate it by palpation on yourself and a partner.



T  
A  
S  
K


**OBSERVE** the following on the skull provided:

On the sides of the neurocranium lie parts of the **temporal bone** and a part of the **sphenoid bone** called the greater wing. Where the greater wing articulates with the adjacent bones of the neurocranium lies a configuration of sutures, called the **pterion**.



On the inside of the neurocranium, a major branch of the **middle meningeal artery** crosses the pterion, tightly applied to the skull bones.

T  
A  
S  
K

**REMOVE** the calvarium  and

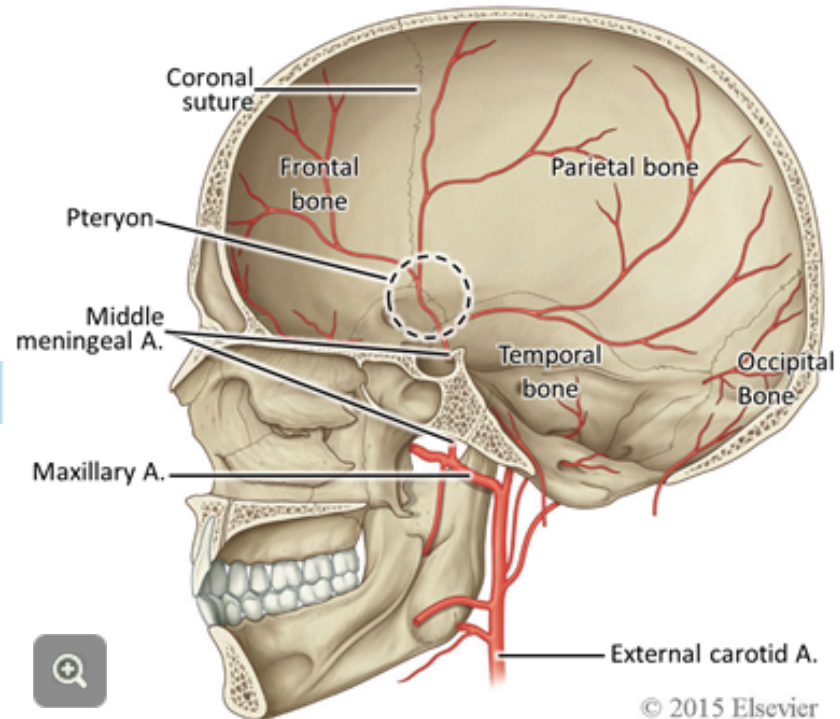
look for the track of the middle meningeal artery on the bones deep to the pterion.

Now hold the skull to the light and confirm that the skull bones are relatively thin in this region.

I  
N  
F  
O

**Because the bone is thin**

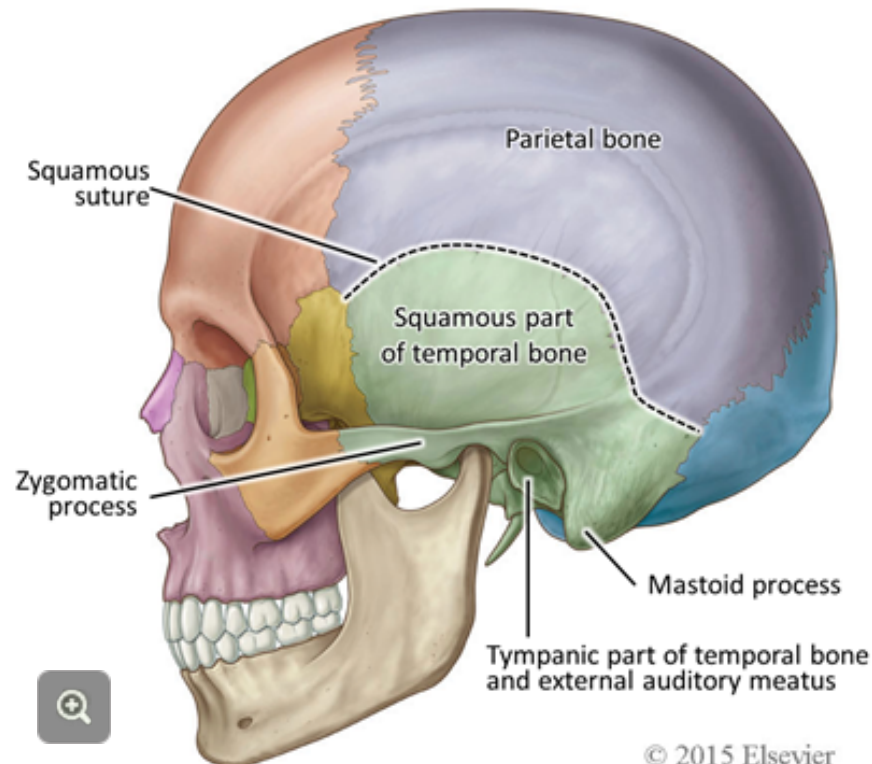
at the pterion, it makes the skull susceptible to fracture in this location (the temple) with the potential to tear the artery and trigger a serious intracranial hemorrhage called an **epidural hematoma**.



The temporal bone is a complex bone with several parts. For now,

T  
A  
S  
K**IDENTIFY:**

the broad thin and flattened **squamous portion** and the **squamous suture** which separates it from the parietal bone; the **tympanic part**, with its opening, the **external auditory meatus**; the **mastoid process**, site of attachment of the **sternocleidomastoid muscle**; and the **zygomatic process** which acts to buttress the facial skeleton against the neurocranium. Palpate both the zygomatic process and the mastoid process on yourself and on a partner.



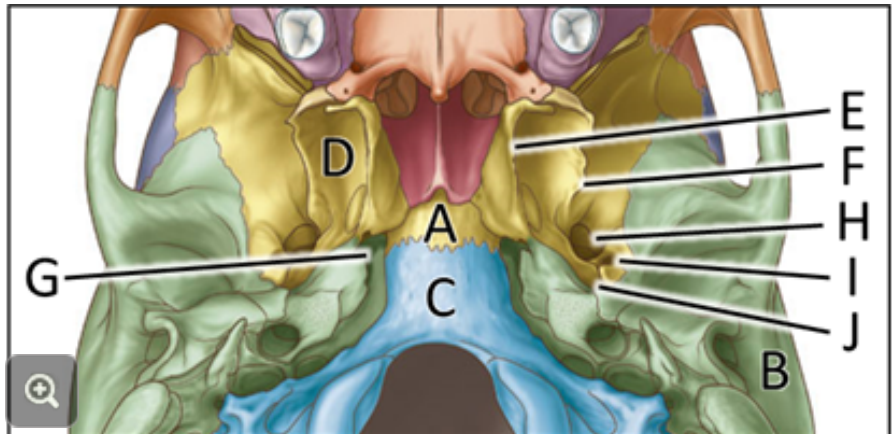
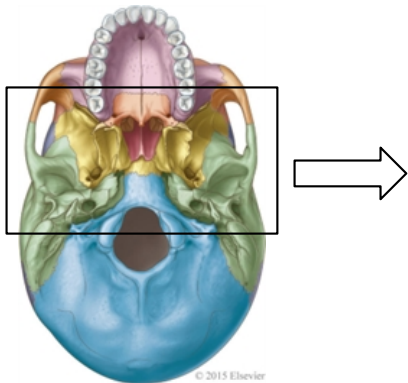


Turn the skull over to identify the features on the inferior surface of the neurocranium.

T  
A  
S  
K

### IDENTIFY:

the **sphenoid bone** (A), **temporal bones** (B) and **occipital bone** (C). Identify the **pterygoid processes** (D) of the sphenoid bone, each of which is composed of a **medial** (E) and **lateral** (F) **pterygoid plate**. Posterior to the medial pterygoid plate, identify the **foramen lacerum** (G). Posterolateral to the lateral pterygoid plate, identify the **foramen ovale** (H) and the **foramen spinosum** (I). Use a pipe cleaner (NOT A PEN!!) to probe these foramina and observe their connections with the interior of the neurocranium. Continuing on the external surface of the skull base, medial to the foramen spinosum, identify the opening to the skeletal part of the **auditory (pharyngotympanic or Eustacian)** tube (J). In life, much of the wall of this tube is cartilaginous.



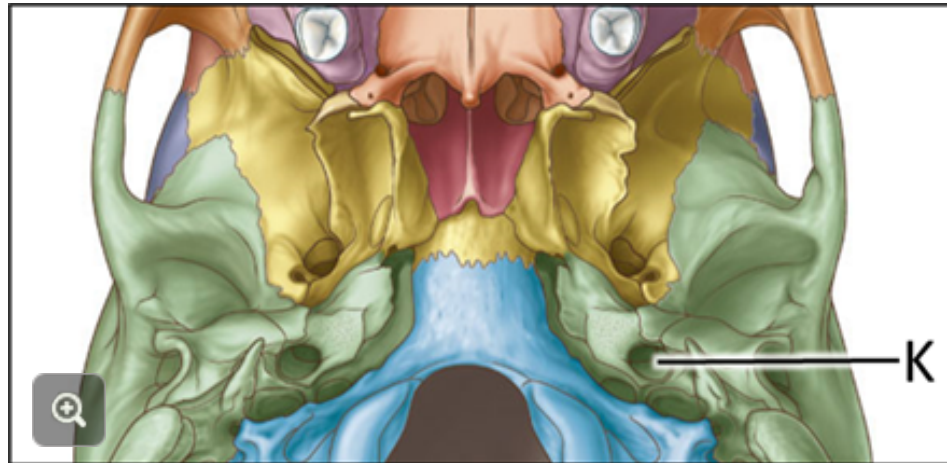
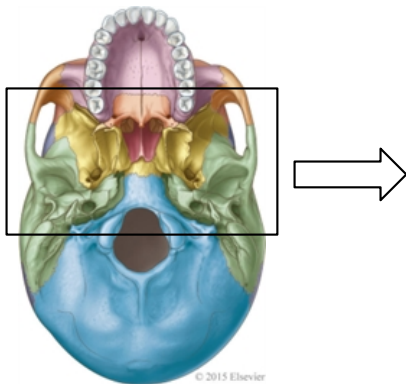


Continuing your study of the inferior surface of the neurocranium,

T  
A  
S  
K

### IDENTIFY:

the entrance to the **carotid canal** (K) posterior to the opening of the auditory tube. The carotid canal runs through the temporal bone. Use a pipe cleaner to probe the carotid canal, and compare the position of the entrance to the canal into the temporal bone from the outside of the neurocranium, with its exit inside the neurocranium. You will observe that the carotid canal opens into the neurocranium over a centimeter anteromedial to its origin. This is truly a “canal”, or tunnel, through the temporal bone through which the internal carotid artery travels in order to gain access to the brain.

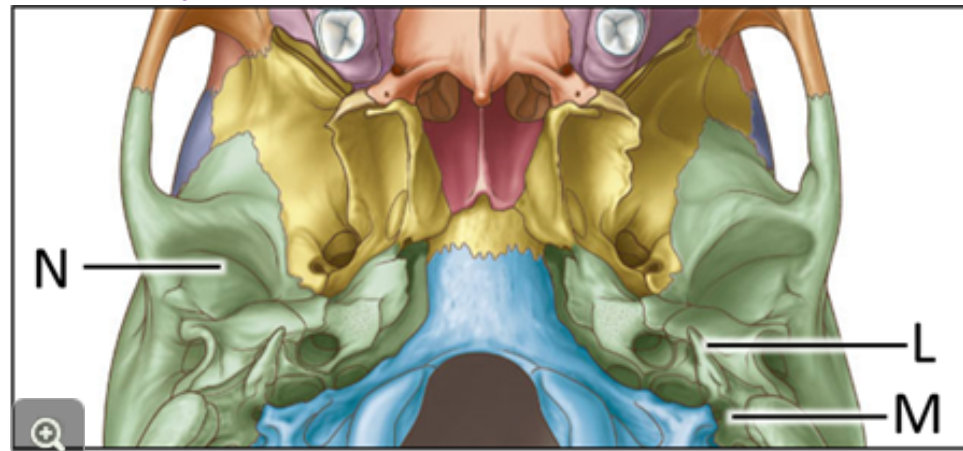

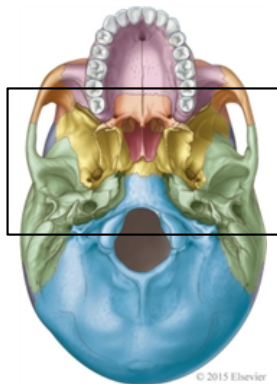


Continuing your study of the inferior surface of the neurocranium,

T  
A  
S  
K

**NEXT:**

see if you can find remnants of the **styloid processes (L)** of the temporal bones **posterolateral to the entrance of the carotid canals**. These long, thin projections of the temporal bone, give attachment to certain muscles and ligaments, but are frequently broken off from the skulls. **Posterior to the styloid processes and medial to the mastoid process, identify the stylomastoid foramen (M)**, the site where the part of the **facial nerve** responsible for innervating the muscles of facial expression exits from the skull. Finally, locate the **mandibular fossa (N)**, which articulates with the **head of the condyloid process** of the mandible to form the **temporomandibular joint**.

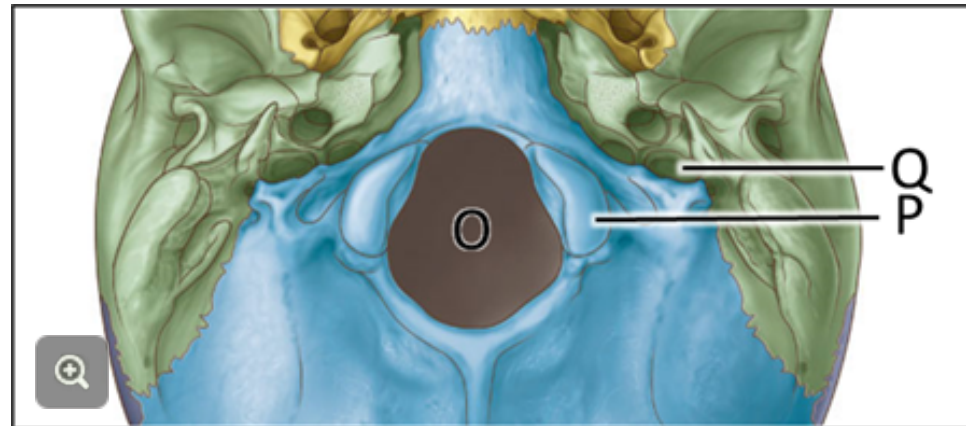
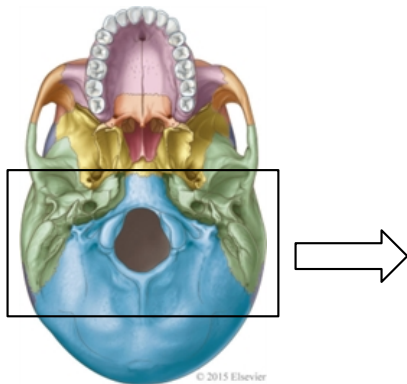


Continuing your study of the inferior surface of the neurocranium,

T  
A  
S  
K

### NEXT:

On the inferior surface of the occipital bone, identify the **foramen magnum** (O) through which the brainstem connects with the spinal cord. On either side of the foramen magnum, identify the **occipital condyles** (P), at which the skull articulates with the atlas (C<sub>1</sub> vertebra) at the atlanto-occipital joints. Nodding movements of the head take place at the atlanto-occipital joints. Locate the openings of the **jugular foramina** (Q) between the condyles and the styloid processes of the temporal bones.



Since embarking on this exercise, you have **identified** the following structures and learned their significance. In the case of foramina, state what structures pass through each.

- the frontal bone, parietal bones, coronal suture, sagittal suture, occipital bone, lambdoid suture, bregma, lambda, external occipital protuberance, temporal bone, greater wing of sphenoid bone, pterion, impression left by the middle meningeal artery on the internal surface of the cranial cavity
- temporal bone: squamous part, squamous suture, tympanic part, external auditory meatus, mastoid process, zygomatic process
- inferior surface of neurocranium: sphenoid bone, temporal bones, occipital bone,
- sphenoid bone: pterygoid process, medial and lateral pterygoid plate, foramen lacerum, foramen ovale, foramen spinosum, opening of the pharyngotympanic tube
- temporal bone: the carotid canal, location of styloid process, stylomastoid foramen, mandibular fossa
- occipital bone: foramen magnum, occipital condyles, jugular foramina

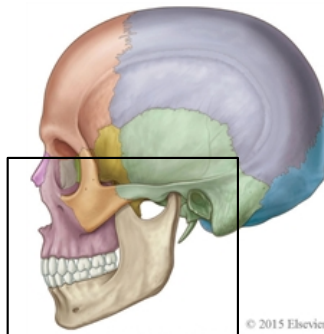
This is a good place to pause and assess your learning. Quiz each other thoroughly. If you are satisfied with your **ability to identify these structures** and **describe their significance**, **move on** to the next stage of the exercise.

The facial bones surround and support the oral cavity, nasal cavity, and orbits.

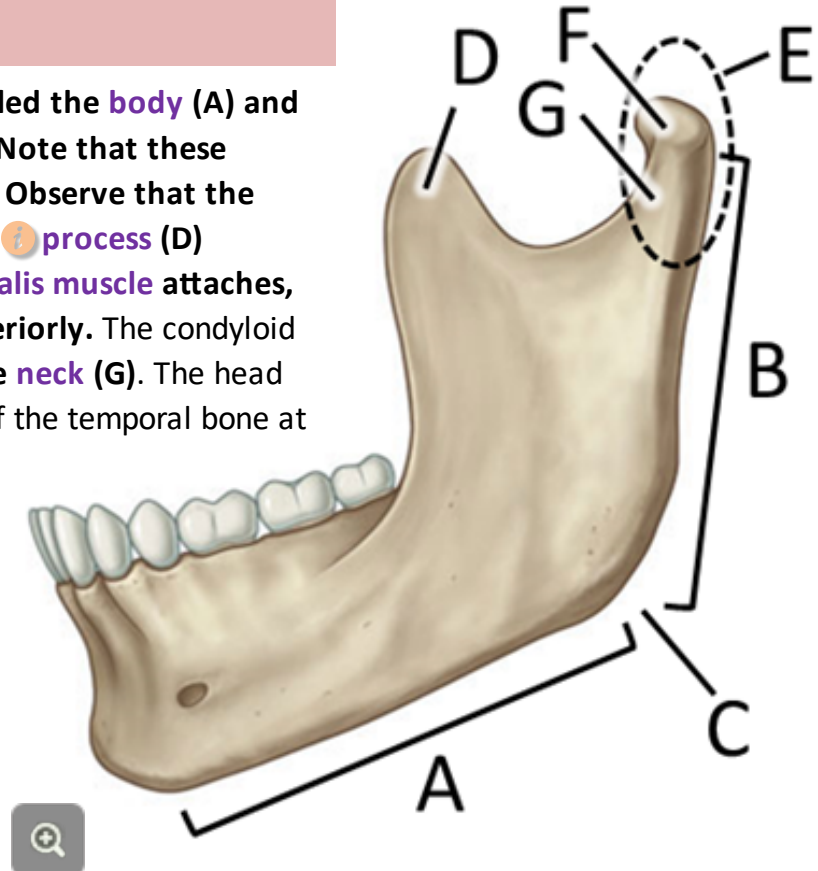
T  
A  
S  
K

**REMOVE** the mandible and observe

that it consists of a horizontal part called the **body (A)** and a vertical part called the **ramus (B)**. Note that these meet at the **angle (C)** of the mandible. Observe that the ramus ends superiorly in the **coronoid process (D)** anteriorly, which is where the **temporalis muscle** attaches, and the **condyloid process (E)**, posteriorly. The condyloid process consists of the **head (F)** and the **neck (G)**. The head articulates with the **mandibular fossa** of the temporal bone at the **temporomandibular joint**.



© 2015 Elsevier

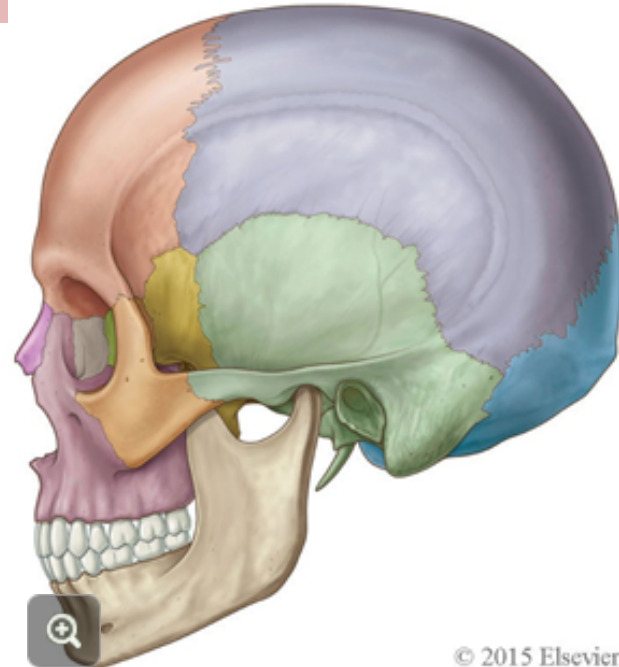


T  
A  
S  
K

**ON your own mandible,**

palpate the body and ramus of the mandible and the angle of the mandible. Note that the coronoid process cannot be felt completely because it lies deep to the zygomatic arch. Next feel the head of the mandible by palpating just anterior to the external auditory meatus. Confirm its identity by feeling the movement of the head at the temporomandibular joint as the mouth is opened and closed.

Sensory innervation to the mandibular region is supplied by the **mandibular division of the trigeminal nerve**. It gives rise to the **inferior alveolar nerves**, which supply the mandibular teeth, and the **mental nerves** which supply the chin and lower lip. The course of these nerves, and their accompanying vessels, through the mandible is described next.



© 2015 Elsevier

Copyright © 2015, 2010, 2002 by Churchill Livingstone, an imprint of Elsevier Inc.

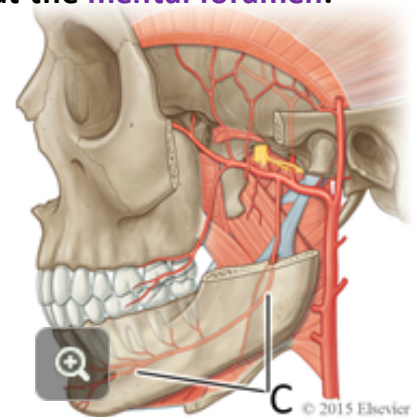
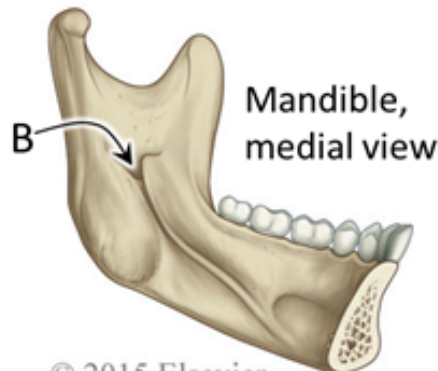
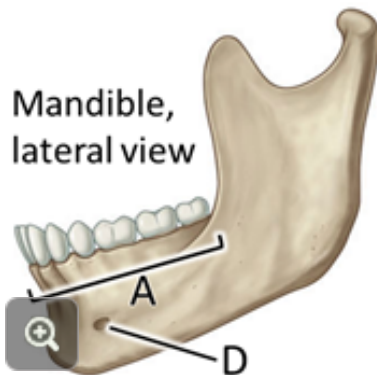
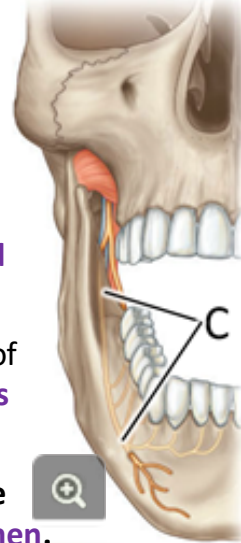
**IDENTIFY the:**

**inferior alveolar process (A)** of the body of the mandible, which develops during infancy to hold the **mandibular teeth** as they erupt.

On the internal surface of the ramus, find the **mandibular foramen (B)**. This is the entrance into the **mandibular canal (C)** for the **inferior alveolar nerves, arteries and veins**, which serve the lower teeth.

The mandibular canal ends at the **mental foramen (D)**. Here, the terminal branches of the inferior alveolar nerves, arteries and veins emerge as the **mental nerves, arteries and veins**, which serve the tissues of the chin.

Find the mental foramen and envision the **mandibular canal** running through the mandible, starting from the **mandibular foramen** and ending at the **mental foramen**.





You will now continue your study of the facial skeleton with the maxillary bones.

Each maxilla contributes to the skeletal structure of the oral, nasal and orbital cavities.

Just inferior to the orbital margin,

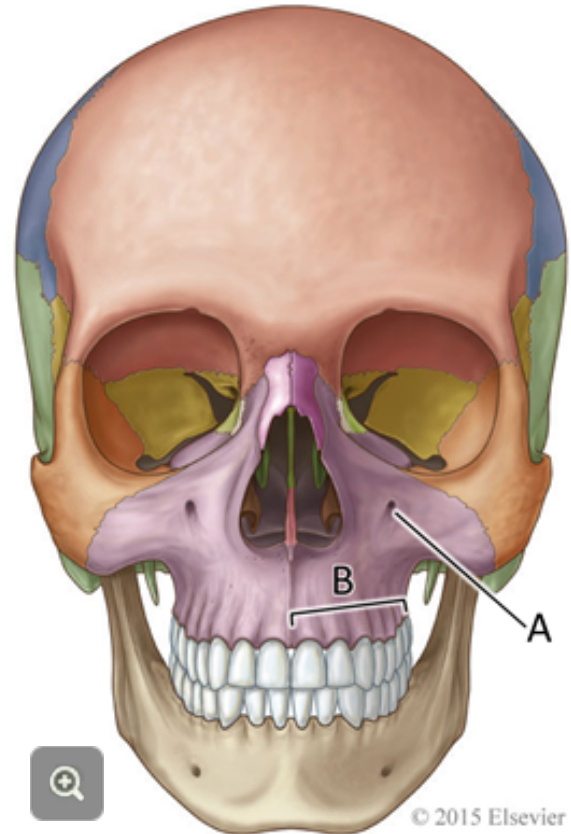
T  
A  
S  
K

**IDENTIFY** the

**infraorbital foramen (A)** through which the **infraorbital branch of the maxillary division of the trigeminal nerve** reaches the skin of the lower eyelid, upper cheek, and upper lip. Try to locate this foramen on yourself by palpation.

On the inferior margin of the maxillary bone, identify the **superior alveolar process (B)**, which houses the upper, or **maxillary teeth**.

The maxillary division of the trigeminal nerve also gives rise to the **superior alveolar nerves**, which serve the upper teeth.





Now turn your attention to the inferior (oral) surface of the maxillary bones. To facilitate this, remove the mandible from the skull. Remember to reattach it when you are finished.

T  
A  
S  
K

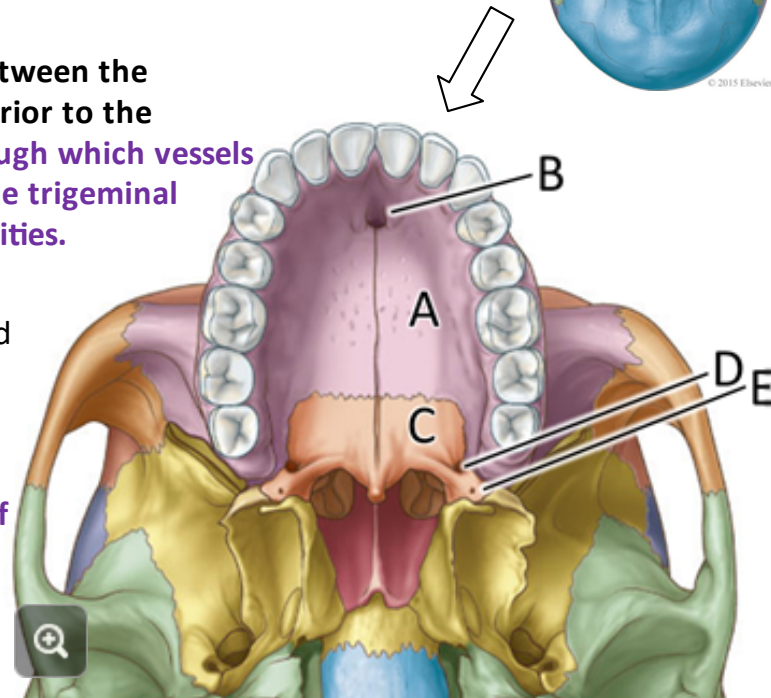
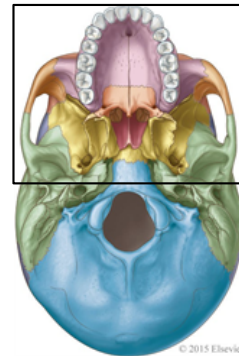
### IDENTIFY the

**palatal processes (A)** of the maxillae, which form much of **the hard palate**. The palate forms the **roof of the mouth** and the **floor of the nasal cavity**.

Anteriorly, identify the **incisive canal (B)** between the palatal processes of the maxillae, just posterior to the medial 2 incisors. **This is a passageway through which vessels and branches of the maxillary division of the trigeminal nerves pass between the nasal and oral cavities.**

The posterior part of the hard palate is formed by parts of the two **palatine bones (C)**.

Identify the **greater (D)** and **lesser (E)** **palatine foramina** in each palatine bone through which **blood vessels and branches of the maxillary division of the trigeminal nerve reach the palate.**

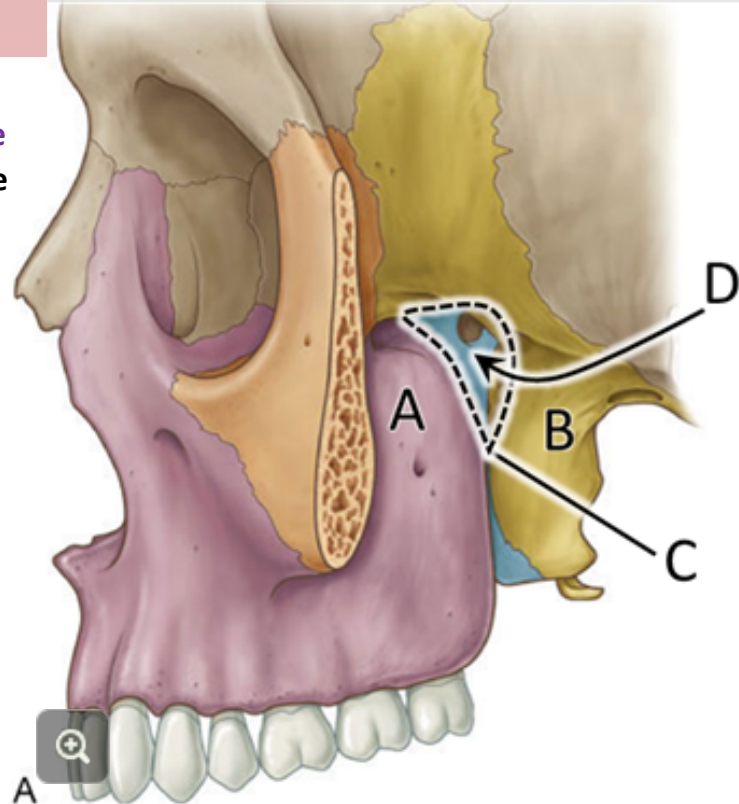


Now, look at the skull from its lateral aspect.

T  
A  
S  
K

### OBSERVE that

posteriorly, the maxillary bones (A) make contact with the pterygoid processes of the sphenoid bone (B) on each side. The slit-like opening between the 2 bones is called the pterygomaxillary fissure (C). The pterygomaxillary fissure leads into a space, called the pterygopalatine fossa (D).



The pterygopalatine fossa in turn makes connections:

ANTERIORLY with the **orbit through the inferior orbital fissure (E)**,

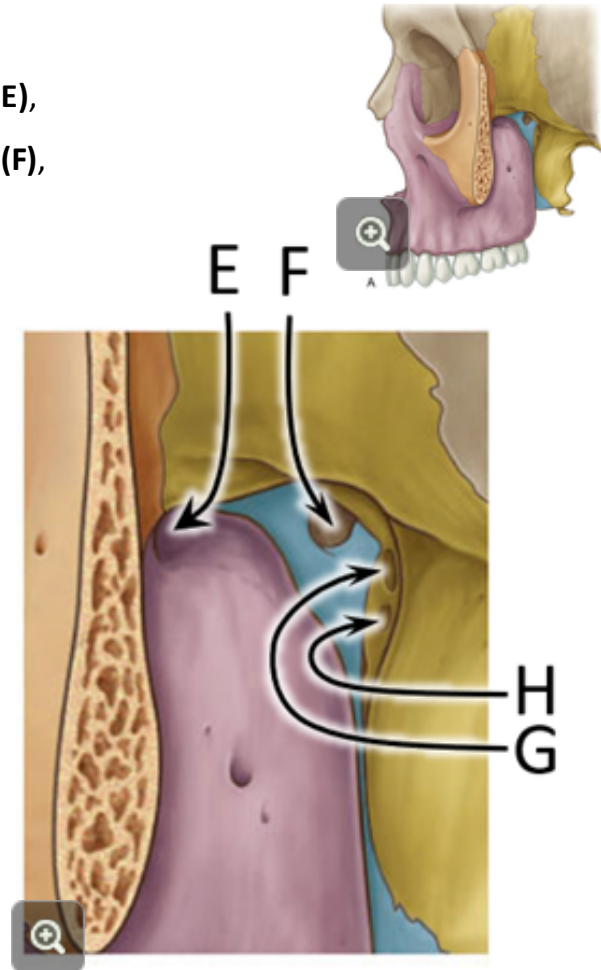
MEDIALY with the **nose through the sphenopalatine foramen (F)**,

INFERIORLY with the **oral cavity through the greater and lesser palatine canals**, and

POSTERIORLY with the **cranial cavity through the foramen rotundum (G) and the pterygoid canal (H)**.

These connections will be important when we study the **infratemporal fossa**.

At this point, appreciate that this space acts as a **junction box** through which nerves and vessels can travel between these various spaces, the cranial cavity, nasal cavity, oral cavity and orbit.



It can be difficult to visualize the characteristics of the fossa on the articulated skull. A brief video tour of the pterygopalatine fossa by Dr. Robert Acland of the University of Louisville, available on YouTube, is an excellent demonstration of the anatomy and connections of this space. You will undoubtedly find it useful to your understanding of the course and connections made by the maxillary nerve and maxillary artery.

Click the video button below to view this resource.

Return to the anterior view of the skull and

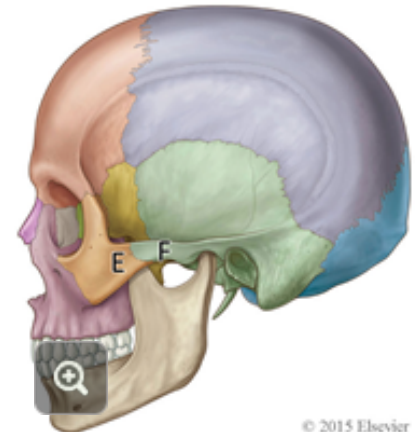
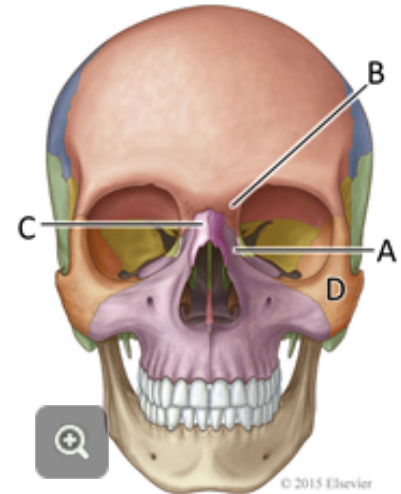
T  
A  
S  
K

**OBSERVE** the

**frontal process of the maxillary bone (A)** passing superiorly to meet the **frontal bone (B)** and forming the **medial border of the orbit**. Between the frontal processes of the two maxillae lie the **2 nasal bones (C)** contributing to the bridge of the nose.

Notice that laterally, each maxilla articulates with a **zygomatic bone (D)**, contributing to the prominence of the cheek. **Observe that the zygomatic bone forms part of the floor and lateral wall of the orbit and articulates with the maxilla, frontal, and temporal bones.**

**Observe that the temporal process of the zygomatic bone (E) and the zygomatic process of the temporal bone (F) together make up the zygomatic arch.** The zygomatic arches, on each side of the skull, buttress the facial skeleton against the neurocranium.



© 2015 Elsevier

© 2015 Elsevier

Several of the bones of the skull contain air-filled spaces, which are often called **sinuses**. Alternatively, if they are arranged as a honeycomb of smaller, connected spaces, they are called **air cells**.

Sinuses lighten the skull and those sinuses that connect with the nasal cavity give resonance to the voice. These spaces are **lined with a mucous-producing membrane** that keeps the lining tissues moist. As the mucus is continuously produced, **there is a need of drainage** for each of these sinuses.

The **temporal bone** contains the **mastoid air cells**, which fill the mastoid process. The mastoid air cells open into the **middle ear cavity**. The middle ear cavity opens into the **nasopharynx via the auditory tube**.

I  
N  
F  
O**OTITIS MEDIA**

The swelling that accompanies inflammation of the lining of the auditory tube can block it and result in the accumulation of fluid in the middle ear cavity. This is painful and can interfere with hearing. Children who experience repeated infections that affect the tissues of the auditory tube may have tubes inserted through the eardrum to provide an alternate route of drainage from the middle ear.

The **paranasal sinuses** are a group of such spaces that open into the nasal cavity. There are four paired sets of paranasal sinuses:

1. The **sphenoid sinus** is contained within the **body of the sphenoid bone**, posteromedial to the orbit.
2. The **ethmoid air cells** are a group of small, interconnected spaces within the **ethmoid bone**, medial to the orbit.
3. The **maxillary sinus** is the largest, and is contained within the **maxillary bone**, inferior to the orbit.
4. The **frontal sinus** is located in the **frontal bone**, superomedial to the orbit.

The paranasal sinuses will be studied in more detail in a later lab exercise on the anatomy of the nasal cavity.

Since embarking on this exercise, in addition to the content of Progress Check 1, you have **identified** the following structures and learned their significance. In the case of foramina, be able to state what structures pass through each.

- the mandible: body, ramus, angle, coronoid process, condyloid process (inc. head and neck), inferior alveolar process, mandibular foramen, mandibular canal, mental foramen
- describe the distribution of the mandibular division of the trigeminal nerve, V3, specifically its branches, the inferior alveolar and mental nerves
- the maxilla: inferior orbital foramen, superior alveolar process
- describe the distribution of the maxillary division of the trigeminal nerve, V2, specifically its branches, the superior alveolar and infraorbital nerves
- the hard palate: palatal process of the maxillae, incisive canal, palatine bones, greater and lesser palatine foramina
- pterygomaxillary fissure and pterygopalatine fossa; through what openings does the pterygopalatine fossa communicate with the i) cranial cavity, ii) nasal cavity, iii) oral cavity and iv) orbit?
- bony orbit: frontal process of maxillary bone, nasal bones, zygoma
- Which 4 bones contain paranasal air sinuses? What are the mastoid air cells and into what space do they open?

If you are satisfied with your **ability to identify these structures** and **describe their significance**, call your AT over for confirmation and for **permission to move on** to the next stage of the exercise.

# 4.2 / 4.4 The Face and Parotid Region

What you'll need:

## RESOURCES

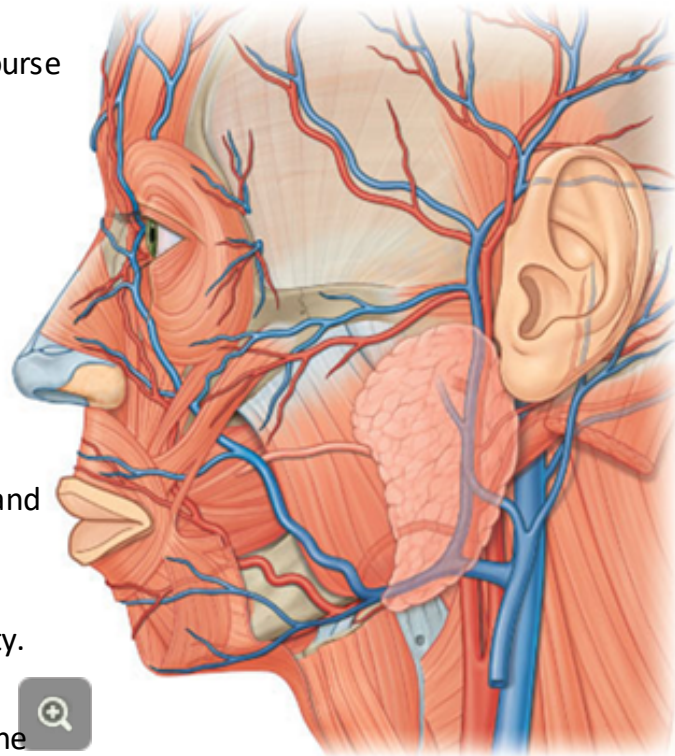
- cadaver 1, both sides

|                 | Session 1     |                | Session 2     |                |
|-----------------|---------------|----------------|---------------|----------------|
|                 | First 90 mins | Second 90 mins | First 90 mins | Second 90 mins |
| right side face | pairs 2       | pairs 1        | pairs 4       | pairs 3        |
| left side face  | pairs 4       | pairs 3        | pairs 2       | pairs 1        |



When you are finished this station, you should be able to identify and / or describe:

1. the location and extent of the parotid gland and the course of its duct.
2. the means by which parasympathetic innervation is delivered to the parotid gland.
3. the masseter and temporalis muscle, both muscles of mastication, including their actions and nerve supply.
4. the buccinator muscle and the orbicularis oris and orbicularis oculi, three of the many muscles of facial expression, including their actions and nerve supply.
5. the origin, course and termination of the facial artery and facial vein.
6. the venous path by which infection can pass from the “danger triangle” of the face into the intracranial cavity.
7. terminal branches of the three subdivisions of the trigeminal nerve, which provide general sensation to the skin of the face.



The **muscles of facial expression** extend from the facial skeleton to insert into the dermis of the skin. They act to move the skin of the face and include the **sphincter muscles** surrounding the eyes and mouth. Motor control to the muscles of facial expression is provided by **the facial nerve, CN VII**

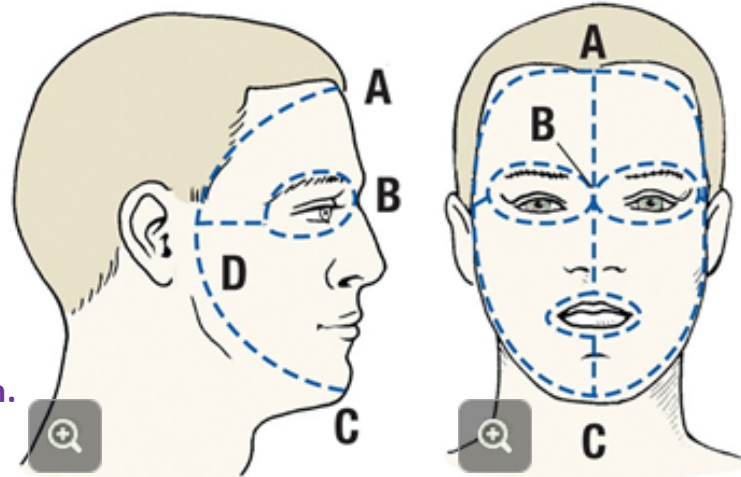
**TASK** REMOVE the skin from both sides of the face,

using the incisions suggested by the diagram below.

Work carefully; this is not a race! There are six hours budgeted for this dissection, and all six are required to complete it! The first pairs to dissect will not see the completed dissection until the end of the six hours. The last pairs to dissect will present the completed dissection to all group members.

**Use a new scalpel blade.** The skin of the face is thin, so take care not to cut too deeply. Be warned that the muscles of the face are relatively pale in colour as compared to muscles you've seen to date (the abdominal muscles), and so can be more difficult to distinguish from surrounding fascia.

**Once the skin is removed, put your scalpel away. You should now be looking at a layer of superficial fascia. You will proceed using only blunt dissection.**



Your first task will be to identify the **parotid duct (A)** and **branches of the facial nerve (B)** superficial to the **masseter muscle (C)** ➡.

T  
A  
S  
K

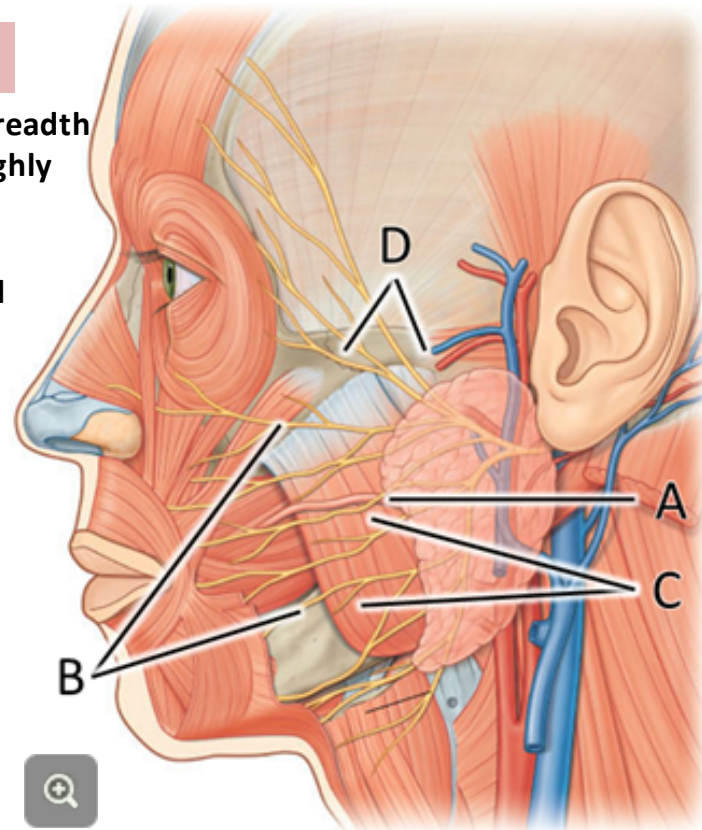
### PALPATE THE ZYGOMATIC ARCH (D).

You will find the **parotid duct** about a finger's breadth inferior to the zygomatic arch, and running roughly parallel to it. It is a little thinner than a pencil.

**Clean it by blunt dissection**, moving your instruments **parallel to** the duct and adjacent branches of the facial nerve. This way, you are less likely to sever them.

You may encounter and clean a few **branches of the facial nerve** as you work, but do not try to complete a full dissection of the branches of the facial nerve.

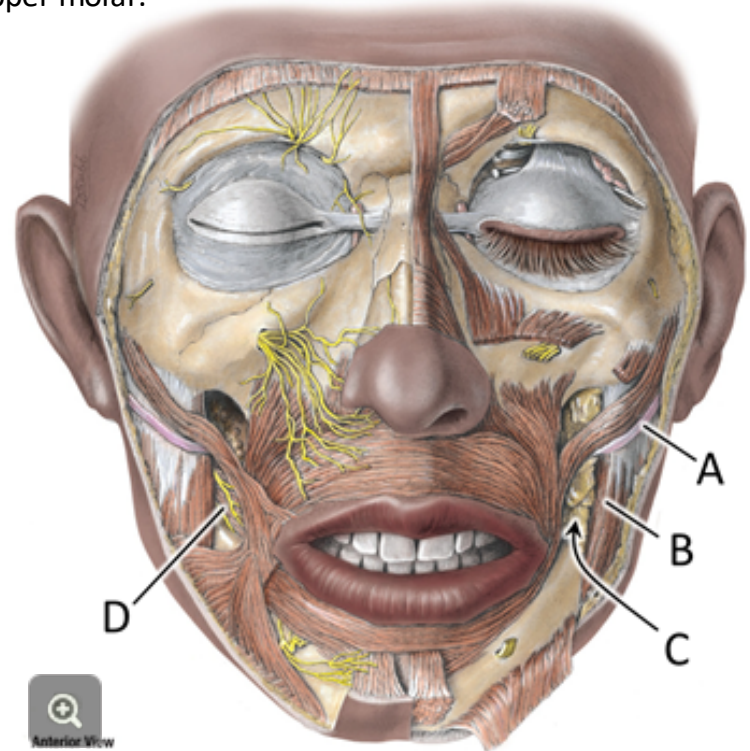
An exceptional dissection demonstrating all motor branches of the facial nerve is available in Grant's Museum and is part of your Field Trip.



As the duct of the **parotid gland** (A) turn medially at the anterior border of the **masseter muscle** (B), it disappears into the **buccal fat pad** (C), a collection of fat that separates the masseter muscle from the underlying **buccinator muscle** (D). The buccal fat pad must be removed in order to see the buccinator muscle, a muscle of facial expression, and appreciate that the parotid duct pierces the buccinator muscle to open into the oral cavity adjacent to the second upper molar.

**T  
A  
S  
K** **AGAIN** using blunt dissection, carefully define the buccal fat pad and ease it from its attachments to surrounding tissues and structures.

If you are patient, it will come out in one piece.





Before going much farther, this is a good time to identify the **facial artery and vein (A)**. These vessels will be found just anterior to the masseter muscle, running parallel to its anterior border. The artery will be anterior to the vein.

T  
A  
S  
K

### USING BLUNT DISSECTION,

clean and identify the **facial artery and vein (A)**, passing superiorly over the body of the mandible, just anterior to the masseter

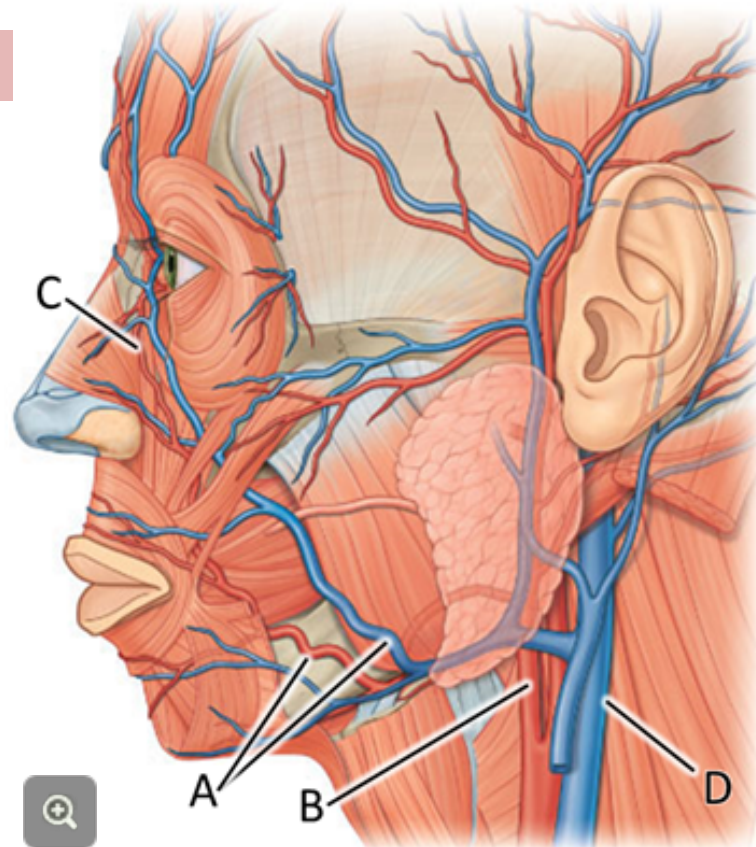
**muscle**. These vessels are quite superficial at this point, so proceed with caution.

**Feel the pulse of the facial artery at this location on yourself and your lab partner.**

**The facial artery is a branch of the external carotid artery (B).** Clean and trace the facial artery superiorly to where it ends as the **angular artery (C)** near the **medial canthus** of the eye.

The facial vein lies just posterior to the facial artery where the vessels cross the mandible. **It is a tributary of the internal jugular vein (D).**

When you are done, you will have revealed the entire course of the facial artery and vein over the mandible and face to the medial canthus of the eye.



The buccinator muscle is a **muscle of facial expression**, and functions to hold the cheek against the teeth when chewing. This keeps food between the **occlusal surfaces of the teeth** during **mastication**.

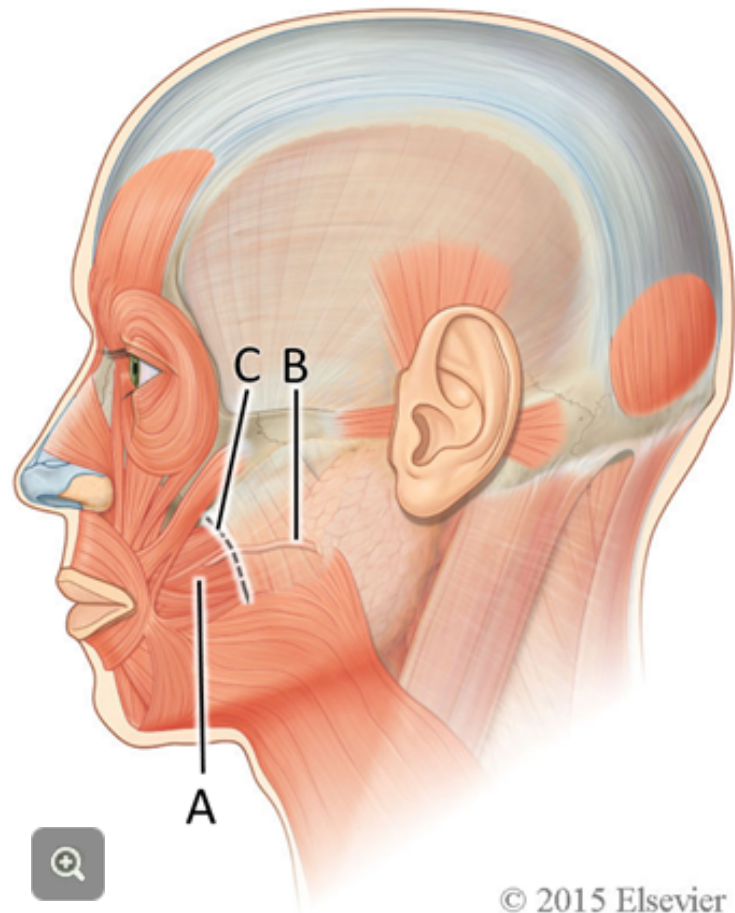
**All muscles of facial expression** (and a few others!) are innervated by the **facial nerve, CN VII**.

**TASK** CONTINUING with blunt dissection,

carefully remove all remaining fat and fascia from the area of the masseter and the facial artery and vein, thus revealing the **buccinator muscle (A)**.

Observe that **the parotid duct (B)** turns medially at the anterior border of the masseter muscle (**C**) to penetrate the buccinator muscle.

The parotid duct penetrates the buccinator muscle to open into the oral cavity on the inside of the cheek **opposite to the upper second molar tooth**.



You can use the parotid duct (A) to guide you to the parotid gland.

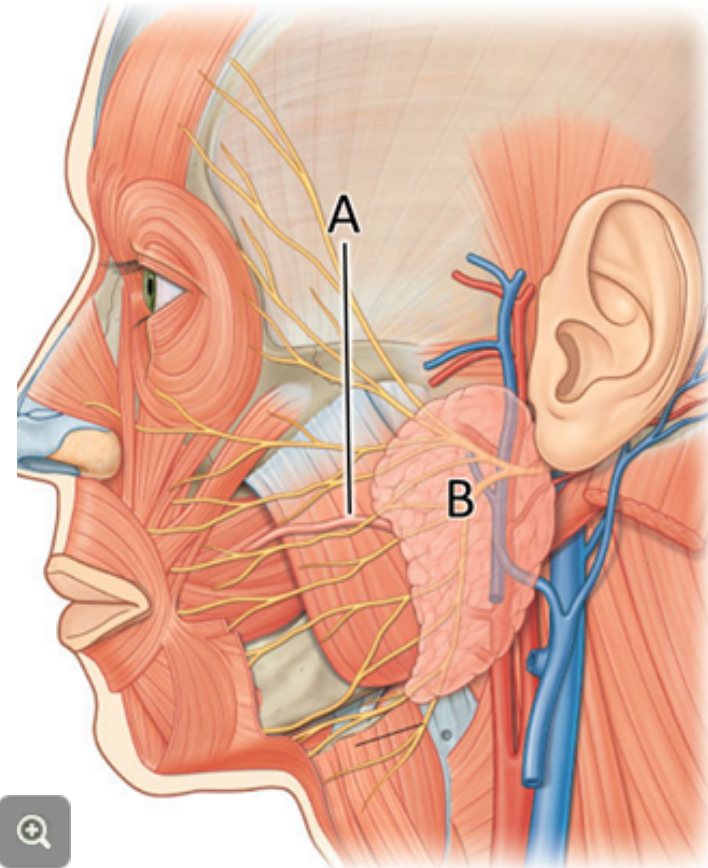
**TASK** USING blunt dissection, follow the duct of the parotid gland posteriorly, until you find the anterior border of the parotid gland itself.

It extends from the zygomatic arch to the angle of the mandible and overlaps both the masseter muscle and the ramus of the mandible. It is enclosed in a dense connective tissue capsule.

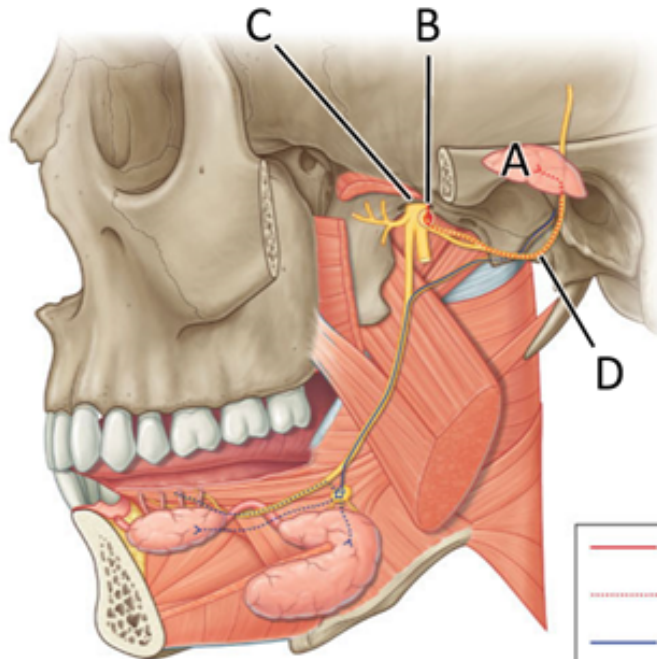
**You will need to use small scissors and the “closed-open” technique to get through this tough capsule.**

**Clean the superficial surface of the parotid gland, and explore its extent, but leave it intact, for now.**

The details of the parasympathetic innervation of the parotid gland are explained on the next slide.



This graphic describes the **parasympathetic innervation of the parotid gland (A)**. For this salivary gland, the preganglionic parasympathetic fibres originate in the **glossopharyngeal nerve, CN IX (B)**. Following a synapse in the **otic ganglion (C)**, the parasympathetic postganglionic fibres join the **auriculotemporal nerve (D)**, a cutaneous branch of V<sub>3</sub>, to travel to the **parotid gland (A)**.



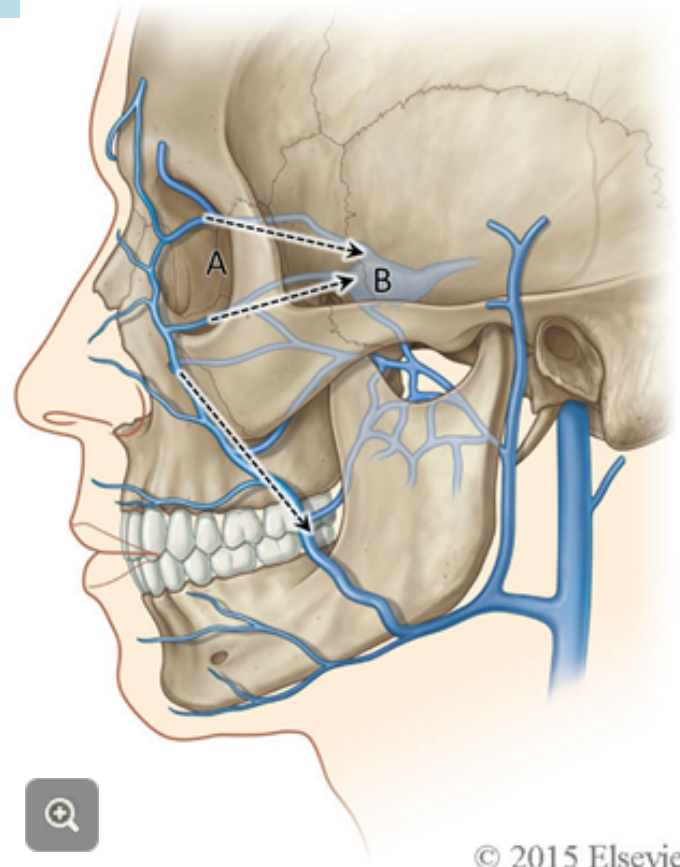
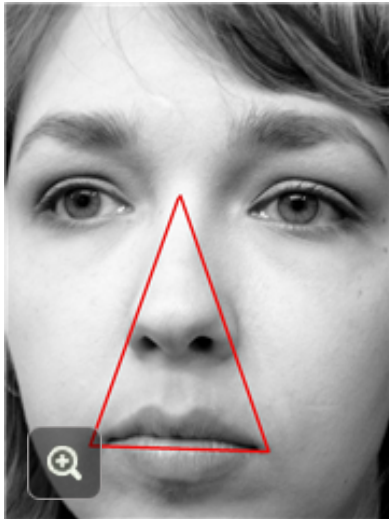
- PreG PSy fibre from IX
- - - PostG PSy fibres travel with the auriculotemporal N.
- PreG PSy fibre from VII
- - - PostG PSy fibres travel with the lingual N.



I  
N  
F  
O

### The “Danger Triangle” of the Face

Tributaries of the facial vein drain blood from the so-called “**danger triangle**” of the face. These tributaries anastomose with veins that drain through the **orbits** (A) and into the **cavernous sinuses** (B) **in the cranial cavity**. It is possible, therefore, that infections in this area can spread intracranially via venous drainage.



T  
A  
S  
K**CLEAN AND IDENTIFY** the

fibres of the **orbicularis oris** encircling the mouth (A).

Carefully remove any remaining skin around the eyelids

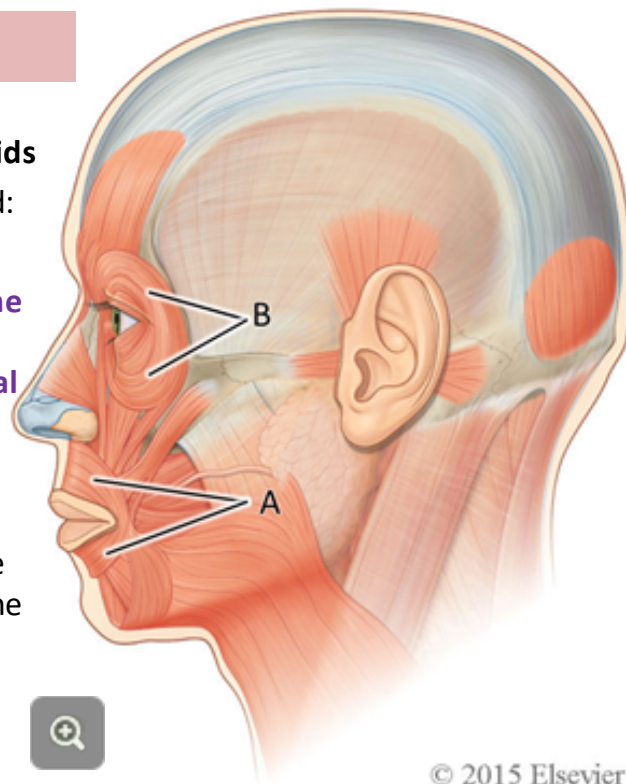
and identify the fibres of the **orbicularis oculi** (B). Be warned: the skin of the eyelids is the thinnest in the body.

**Orbicularis oris purses the lips** and **orbicularis oculi closes the eyelids**. Both belong to the group of muscles known as the **muscles of facial expression**, which are innervated by the **facial nerve, CN VII**.

You have already identified one other muscle of facial expression, the **buccinator**. Also included in this group are a large number of small muscles that arise from the bones of the facial skeleton and attach to the skin. They are important for the movements of the facial skin necessary for proper speech, and to create facial expressions. Do not learn the details of these remaining muscles.

I  
N  
F  
O**Paralysis of the Muscles of Facial Expression**

Paralysis of these muscles will lead to abnormal facial expression, drooling, and inability to close the eye. Inability to close the eye can make it susceptible to injury, and if it cannot be closed properly, the conjunctiva can dry out and ulcerate.



The **facial nerve** (A) exits the skull through the **stylomastoid foramen** and enters the **parotid gland** (B). The stylomastoid foramen, as its name suggests, lies between the **styloid process** (C) and the **mastoid process** (D). Within the parotid gland the facial nerve forms the **parotid plexus** (E), which gives rise to the many branches innervating the **muscles of facial expression**.

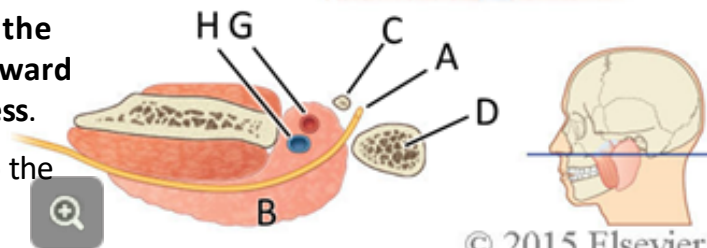
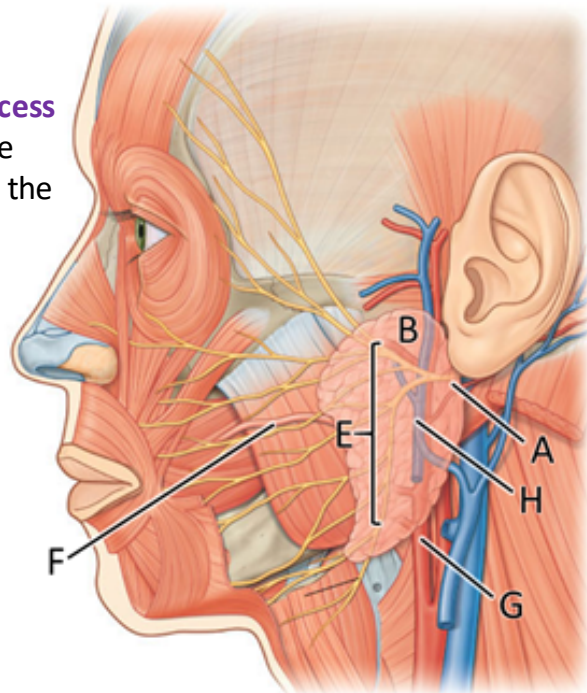
**TASK** IDENTIFY one of the branches

of the facial nerve leaving the anterior edge of the parotid gland. A branch running parallel and adjacent to the **parotid duct** (F) is a good choice.

Carefully, trace it back into the parotid gland using the closed-open scissor technique and removing the gland piecemeal, as necessary.

You will discover that parotid plexus converges within the gland to form the main trunk of the nerve. Follow it as it passes superficial to the external carotid artery (G) and the retromandibular vein (H). Trace the main trunk back toward the stylomastoid foramen, medial to the mastoid process.

You will not be able to trace the facial nerve all the way to the stylomastoid foramen, but **do find its main trunk and demonstrate its relationship to G and H, as described.**



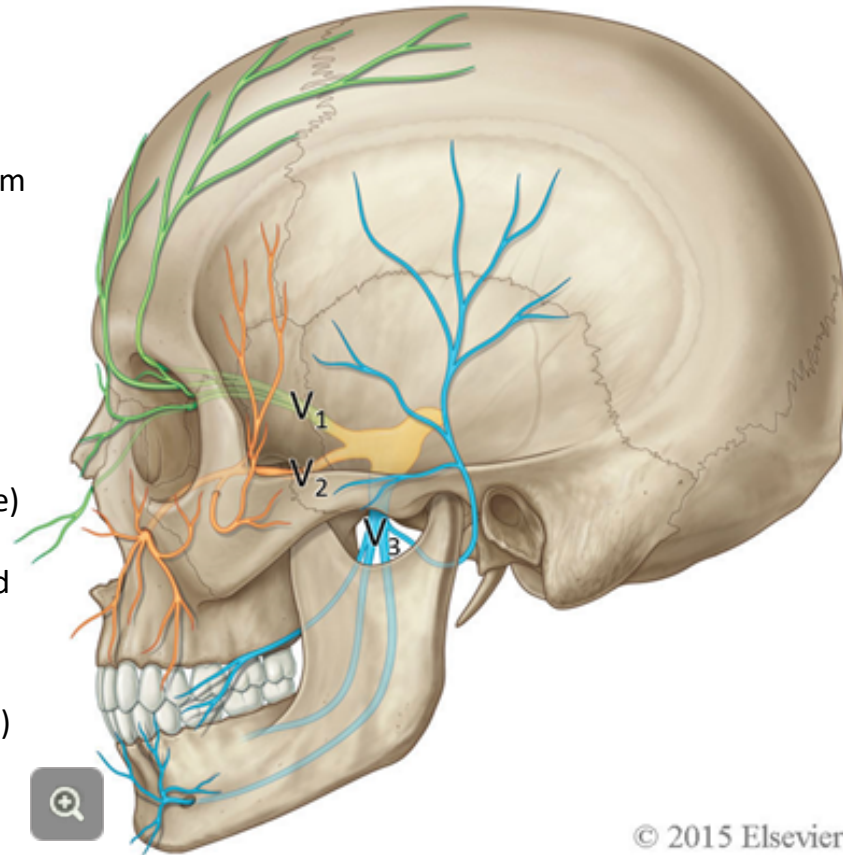
Recall that **general sensation from the face** is carried by the three divisions of the **trigeminal nerve, CN V**. These are the ophthalmic, the maxillary and the mandibular divisions, also known as  $V_1$ ,  $V_2$  and  $V_3$ , respectively.

Once again, examine the accompanying diagram as you read the following:

Branches of the **ophthalmic division,  $V_1$** , (green) supply general sensory fibres to the forehead, the upper eyelid, the contents of the orbit and the tip of the nose, including portions of the nasal septum.

Branches of the **maxillary division,  $V_2$** , (orange) supply sensory fibres to the skin of the lower eyelid, the side of the nose, both externally and internally, the upper cheek, the temple, the maxillary teeth, palate, and the upper lip.

Branches of the **mandibular division,  $V_3$** , (blue) supply sensory fibres to the skin anterior to the ear, over the lower cheek, jaw, mandibular teeth, the floor of the mouth, the lower lip and chin.



The **supraorbital nerve** is a branch of the **ophthalmic division** of the **trigeminal nerve (V<sub>1</sub>)**. It accesses the face via the **supraorbital foramen / notch**, just superior to the margin of the orbit.

It, along with the **supratrochlear branch of V<sub>1</sub>**, innervates the **skin of the upper eyelid** and that of the **forehead up to the vertex of the scalp** 📍.

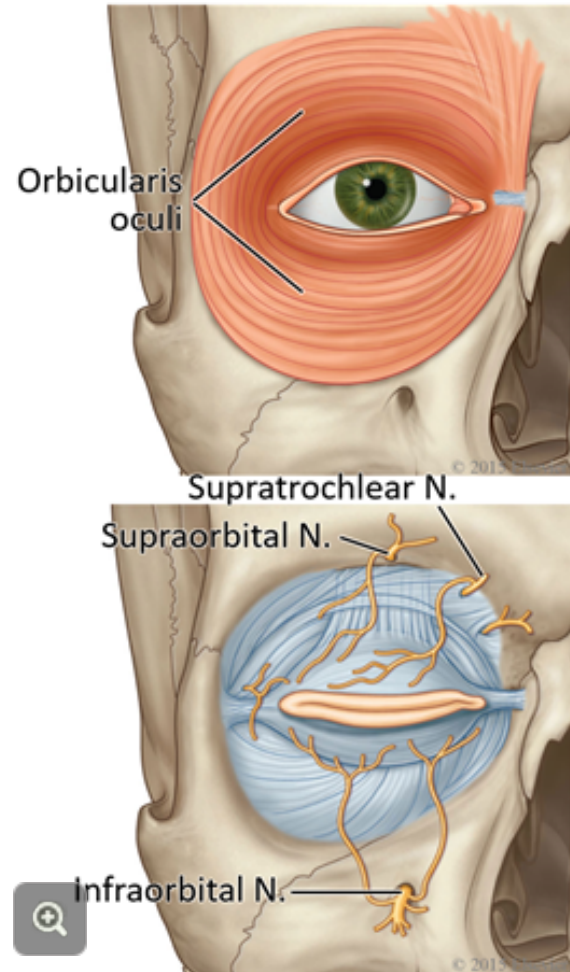
You will next reveal the supraorbital nerve deep to the orbicularis oculi.

T  
A  
S  
K

**USING** blunt dissection,

define the superior border of the **orbicularis oculi**. Reflect the muscle inferiorly to **expose**

**the supraorbital nerve** emerging from the supraorbital foramen / notch. It may help to use your finger to find the foramen / notch by feel.





The **infraorbital nerve** is a branch of the **maxillary division** of the **trigeminal nerve (V<sub>2</sub>)**. It accesses the face via the **infraorbital foramen** to innervate the skin of the lower eyelid, the side of the nose, the upper cheek and upper lip 🔄.

The infraorbital foramen is located inferior to the orbicularis oculi, deep to a muscle of facial expression called the levator labii superioris.

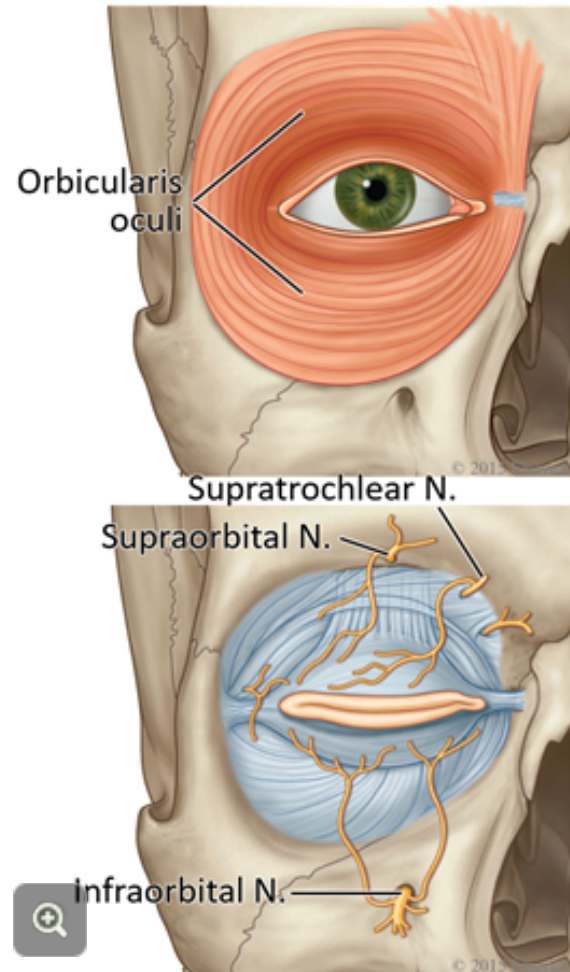
You will next reveal the infraorbital nerve using the levator labii superioris muscle as a landmark.


T  
A  
S  
K

**USING blunt dissection,**

**define the borders of the levator labii superioris muscle** 🔄. Slip closed scissors deep to it, gently

**lifting the muscle away from the underlying maxillary bone. Transect the muscle where it meets the orbicularis oculi, and reflect it downward to expose the infraorbital nerve.**

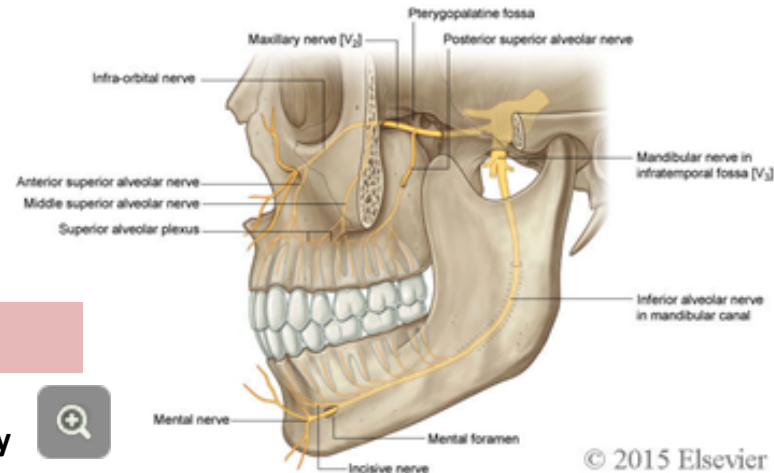


The **mental nerve** is a branch of the **mandibular division** of the **trigeminal nerve (V<sub>3</sub>)**. It accesses the face via the **mental foramen** to innervate the skin of the chin and lower lip .

It arrives at the mental foramen after having traveled through the mandible within the **mandibular canal**. There, it was known as the **inferior alveolar nerve**, and provided sensation to the **mandibular teeth**.

The mental foramen is located inferior to the orbicularis oris, deep to a muscle of facial expression called the depressor anguli oris.


You will next reveal the mental nerve using the depressor anguli oris muscle as a landmark.



© 2015 Elsevier

T  
A  
S  
K

**USING blunt dissection,**

**define the borders of the **depressor anguli oris** .** Slip closed scissors deep to it, gently lifting the muscle away from the underlying mandible. Transect the muscle superiorly, and reflect it downward to **expose the mental nerve**.

Since embarking on this exercise, you have **identified** the following structures and / or learned their significance. In the case of foramina, state what passes through each. In the case of muscles, state their action and innervation. In the case of nerves and arteries, describe their distribution.

- parotid duct, branches of the facial nerve, masseter muscle, buccal fat pad, buccinator muscle; where does the parotid duct open into the oral cavity?
- facial artery and vein; from what vessels does each arise? into what vessels does each drain?
- parotid gland; describe its parasympathetic innervation by the branches of the glossopharyngeal and mandibular nerves
- what is the “danger triangle” of the face?
- orbicularis oris and orbicularis oculi
- facial nerve, external carotid artery and retromandibular vein
- describe the distribution of the three branches of the trigeminal nerve, and specifically the supraorbital, supratrochlear, infraorbital and mental nerves

If you are satisfied with your **ability to identify these structures** and **describe their significance**, call your TA over for confirmation and for **permission to move on** to the next stage of the exercise.



# 4.3 The Infratemporal Fossa

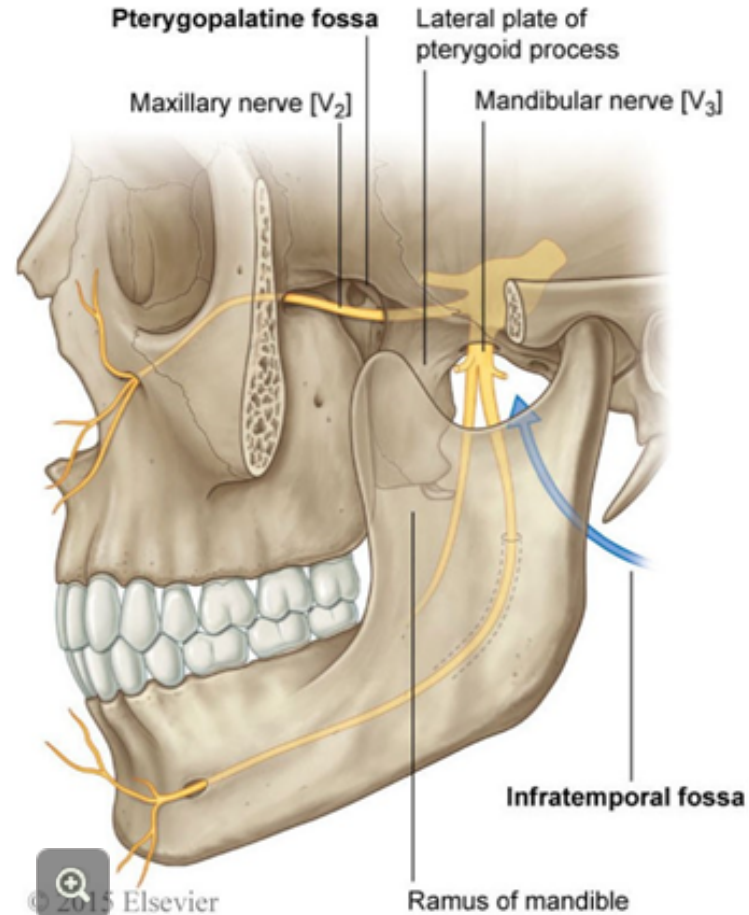
What you'll need:

## **SPECIMENS**

- skull
- superficial prosection of the infratemporal fossa
- deep prosection of the infratemporal fossa

When you finished this exercise, you should be able to identify and / or describe:

1. the borders of the infratemporal fossa
2. the borders of the pterygopalatine fossa
3. the medial and lateral pterygoid muscles, their actions and nerve supply
4. the blood vessels of the infratemporal fossa
5. the branches of the mandibular division of the trigeminal nerve associated with the infratemporal fossa
6. the role of the chorda tympani and lingual nerves in delivering taste fibres to the anterior 2/3 of the tongue and parasympathetic fibres to the salivary glands in the floor of the mouth
7. the role of the glossopharyngeal and auriculotemporal nerves in delivering parasympathetic fibres to the parotid gland





T  
A  
S  
K

### ON THE SKULL, IDENTIFY

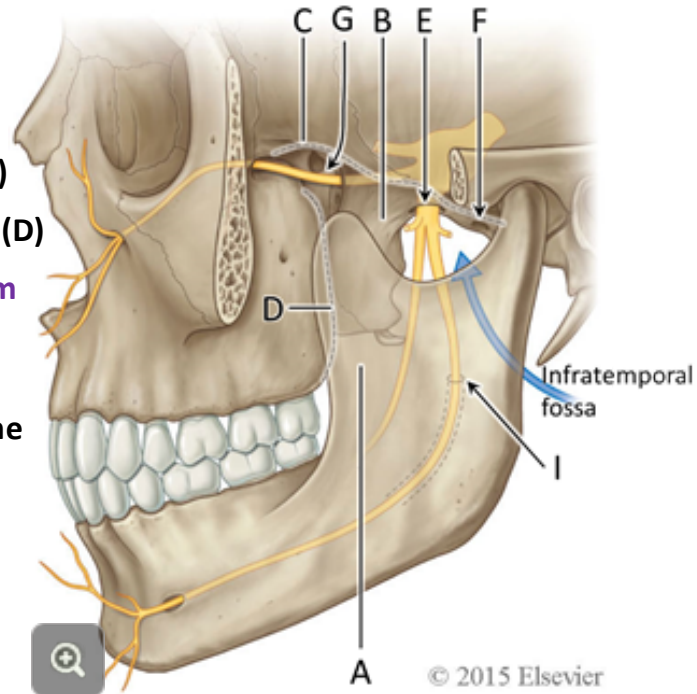
the borders of the infratemporal fossa.

These are:

- laterally: the **ramus of the mandible (A)**
- medially: the **lateral plate of the pterygoid process (B)**
- superiorly: the **inferior surface of the neurocranium (C)**
- anteriorly: the **posterior surface of the maxillary bone (D)**

Identify the **foramen ovale (E)** and the **foramen spinosum (F)** which connect the braincase with the infratemporal fossa.

Identify the **mandibular foramen (I)**, which opens into the interior of the ramus of the mandible from the infratemporal fossa.



## 4.3 The Pterygopalatine Fossa

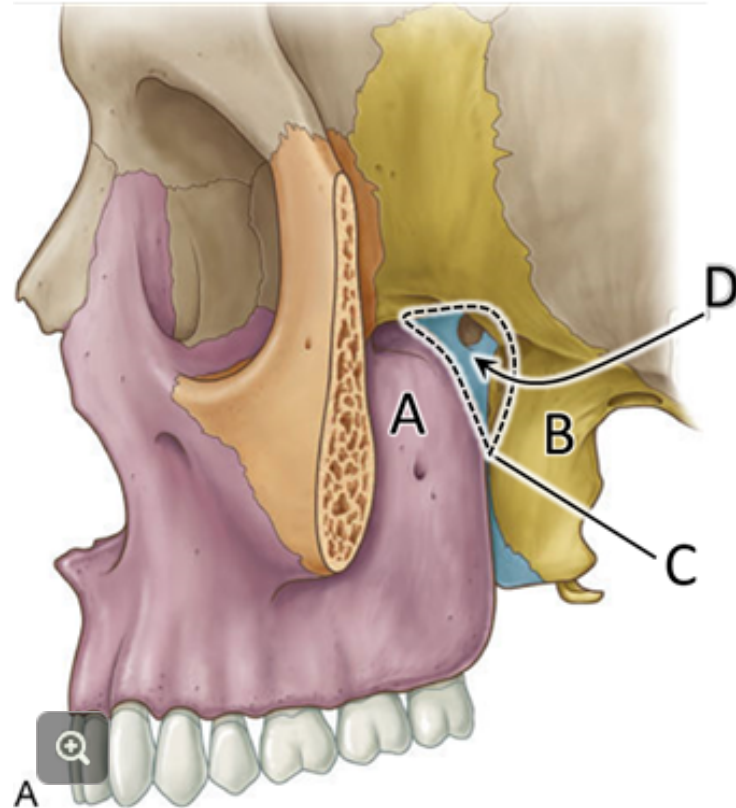


Now, look at the skull from its lateral aspect.

T  
A  
S  
K

### OBSERVE THAT

posteriorly, the maxillary bone (A) makes contact with the pterygoid process of the sphenoid bone (B). The slit-like opening between the 2 bones is called the pterygomaxillary fissure (C). The pterygomaxillary fissure leads into a space, called the pterygopalatine fossa (D).



## 4.3 The Superficial Infratemporal Fossa



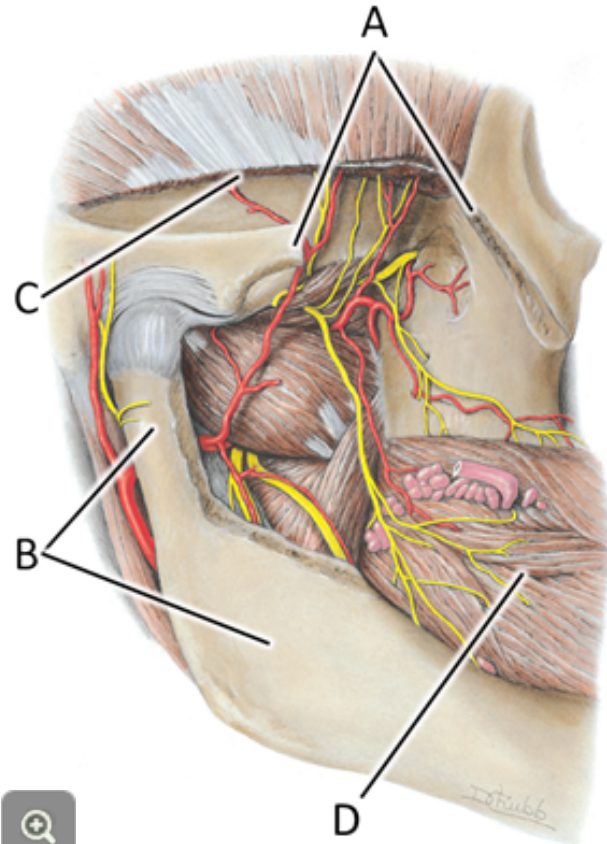
To prepare the prosections of the infratemporal fossa, the zygomatic arch and masseter muscle have been removed. In addition, the upper portion of the ramus of the mandible together with the lower fibres of the temporalis muscle have been removed, leaving behind the neck and head of the mandible.

T  
A  
S  
K

**UNWRAP** the prosection of the


**SUPERFICIAL** infratemporal fossa. To orient yourself to the specimen, start by identifying the cut ends of the **zygomatic arch (A)**, the remaining parts of the **neck and ramus (B) of the mandible** and the cut edge of the **temporalis major muscle (C)**.

Identify the **buccinator muscle (D)**, a muscle of facial expression.

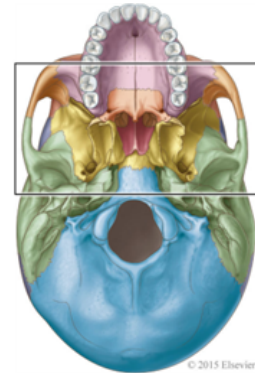


## 4.3 The Medial and Lateral Pterygoid Muscles



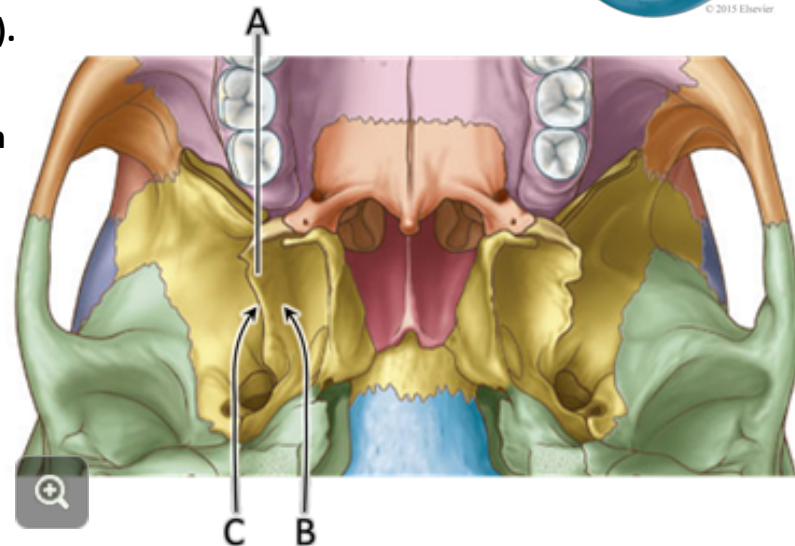
The **medial** and **lateral pterygoid muscles** belong to a group of four muscles called the **muscles of mastication**, along with the **masseter**  and **temporalis muscles**. You'll recall from the prelab SLM that **the muscles of mastication are innervated by motor branches of the mandibular division of the trigeminal nerve, V<sub>3</sub>**.

The medial and lateral pterygoid muscles are **located in the infratemporal fossa**. They both originate from the **lateral pterygoid plate**.



**T**  
**A**  
**S**  
**K** **ON** the bony skull,  
notice that the lateral pterygoid plate (A) has  
a **medial surface** (B) and a **lateral surface** (C).

These are the points of origin of the medial and lateral pterygoid muscles, respectively, and it's on this basis that they are named.







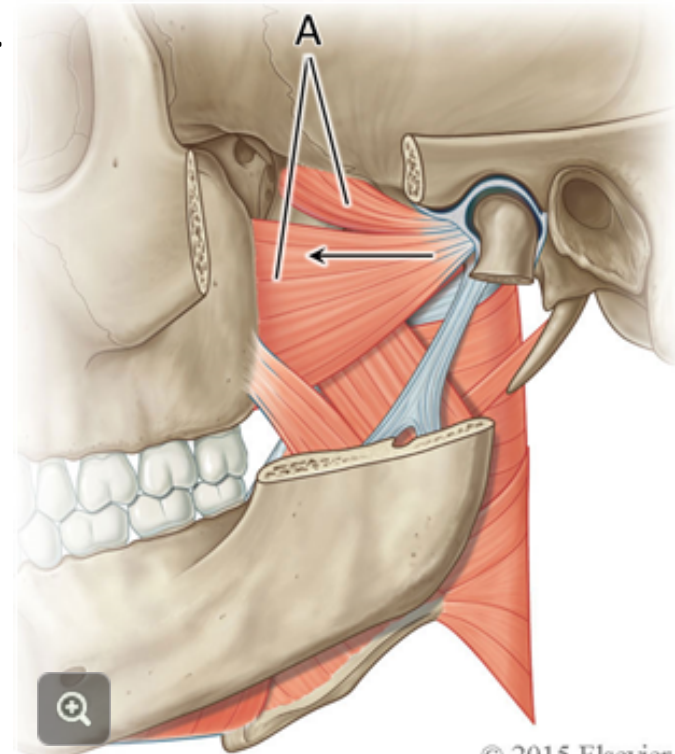
### TASK IDENTIFY the lateral pterygoid muscle (A)

passing horizontally from the **lateral surface of the lateral pterygoid plate to the neck of the mandible.**

Part of its attachment is also into a fibrocartilaginous disc that lies within the cavity of the temporomandibular joint. The **lateral pterygoid muscle** helps to **pull the neck of the mandible anteriorly when the mouth opens.** This movement is called **protrusion** or **protraction** of the jaw.

### TASK PALPATE, on yourself,

**the head of your mandible in the temporomandibular joint, just anterior to the external auditory meatus and confirm how it slides anteriorly as you open your mouth.**



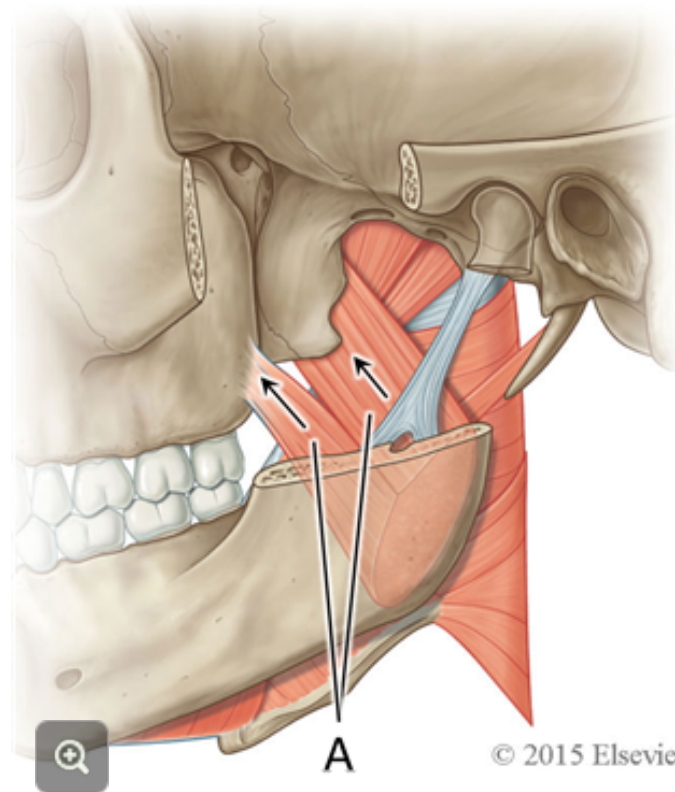


**T  
A  
S  
K** IDENTIFY the **medial pterygoid muscle (A)**

arising from the medial surface of the lateral pterygoid plate and posterior surface of the maxilla. Follow its fibres inferiorly and posteriorly to their attachment to the **medial surface** of the mandible near the angle.

The medial pterygoid muscles on both sides act together in **elevation and protrusion / protraction of the mandible**.

One medial pterygoid **acting alone** will play a role in helping to rotate the mandible **to the opposite side**, for example when grinding your teeth.





## 4.3 The Maxillary Artery and its Branches



9

**TASK** IDENTIFY the **external carotid artery (A)** 

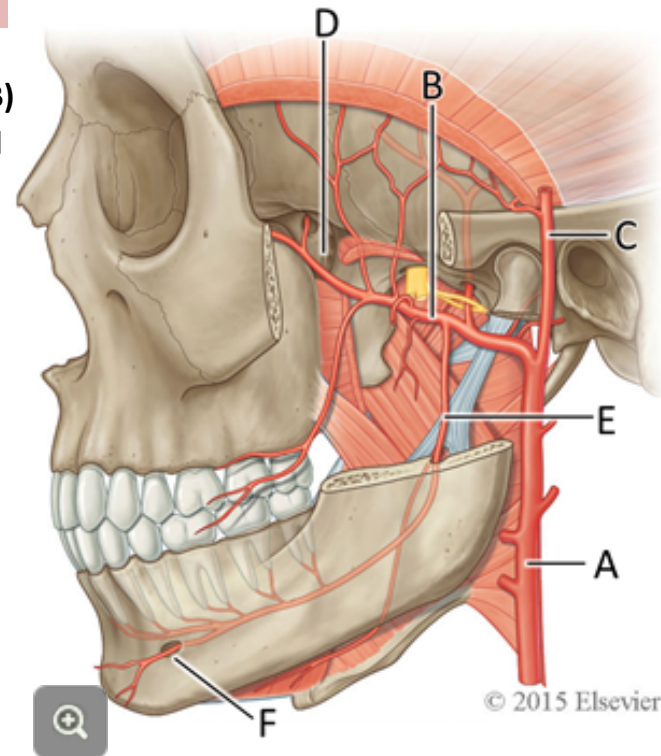
**posterior to the infratemporal fossa, and trace it to where it ends by dividing into the maxillary artery (B) and superficial temporal artery (C).** The superficial temporal artery crosses the zygomatic process of the temporal bone just anterior to the external auditory meatus.

**Palpate the pulse of the superficial temporal artery on yourself and a lab partner** (but take your glove off first).

**On the prosection, if possible (no dissecting!) trace the maxillary artery anteriorly into the infratemporal fossa, as it makes its way toward the pterygomaxillary fissure (D).** Part of its course in this particular prosection may be obscured by the pterygoid muscles but it will be seen in its entirety in the specimen of the **deep infratemporal fossa**.

**In the present specimen, however, identify the inferior alveolar branch of the maxillary artery (E) entering the mandibular canal in the ramus of the mandible.** In an intact specimen, the actual point of entry into the mandibular canal is the **mandibular foramen**.

The **inferior alveolar artery** passes through the mandible supplying branches to the mandibular teeth. It ends by emerging from the **mental foramen** as the **mental artery (F)** to supply the tissues of the chin.



© 2015 Elsevier



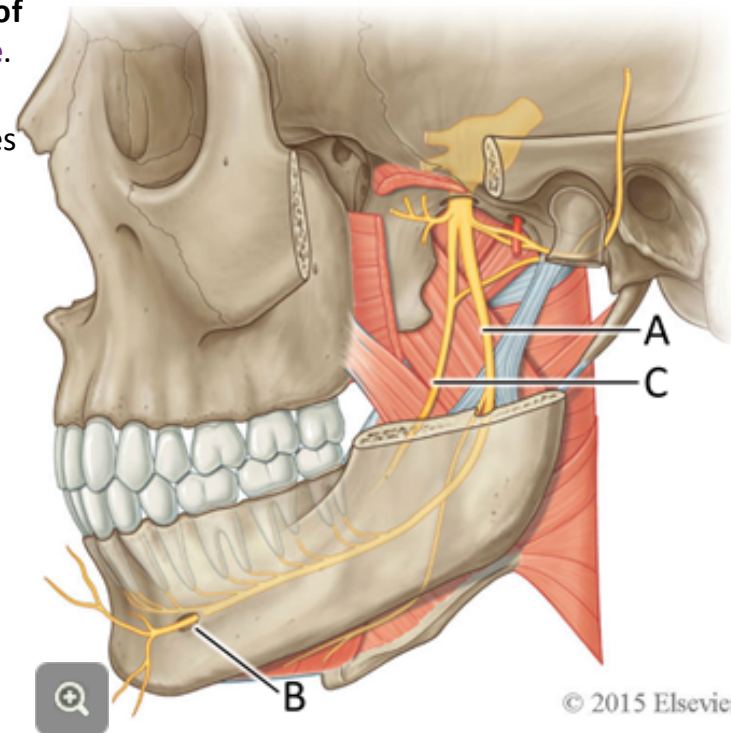
### TASK

**IDENTIFY** on the prosection, accompanying the inferior alveolar artery through the mandibular canal, the **inferior alveolar nerve (A)**, a branch of the **mandibular division of the trigeminal nerve**.

The inferior alveolar nerve accompanies the inferior alveolar artery through the mandible, supplying branches to the teeth. It ends as the **mental nerve (B)**, supplying sensory fibres to the tissues of the chin.

**Anterior to the inferior alveolar nerve in the infratemporal fossa identify the **lingual nerve (C)**, another branch of the mandibular division of the trigeminal nerve.**

The lingual nerve supplies sensory fibres to the floor of the mouth and the anterior 2/3 of the tongue.



## 4.3 The Deep Infratemporal Fossa



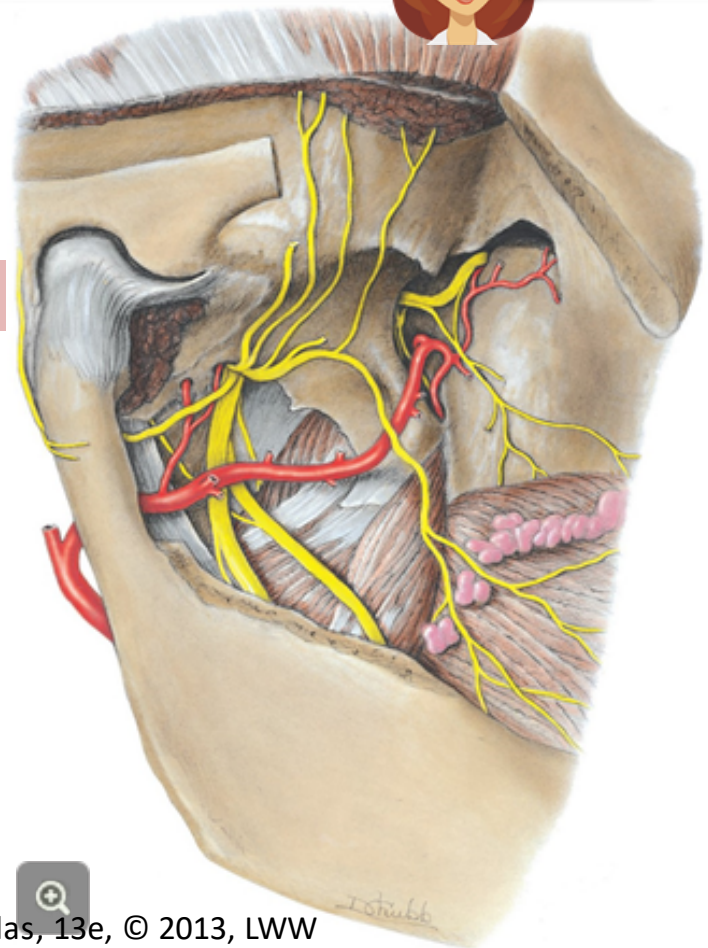
In the specimen of the **deep infratemporal fossa**, the lateral pterygoid muscle has been removed in order to better demonstrate the nerves and vessels that travel through the infratemporal fossa.

You can still see the **buccinator muscle**.

T  
A  
S  
K

**UNWRAP** the prosection of the



**deep infratemporal fossa. Keep the prosection of the superficial infratemporal fossa moist and covered, but handy for comparison as needed, while you study the prosection of the deep infratemporal fossa.**

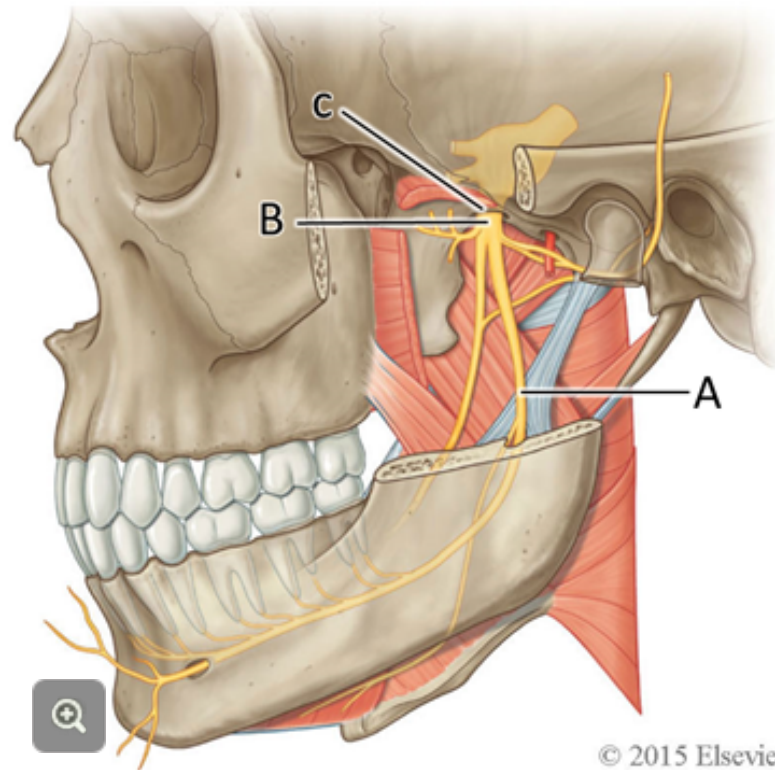


T  
A  
S  
K

**IDENTIFY** in this prosection,

the **inferior alveolar nerve (A)** and trace it superiorly to where it arises as a **branch of the mandibular division of the trigeminal nerve (B)**, just as  $V_3$  passes through the **foramen ovale (C)** to enter into the infratemporal fossa.



As it passes through the foramen ovale, the mandibular nerve divides into a number of motor and sensory branches. The **motor branches supply each of the four muscles of mastication** , and four other muscles . **Do not attempt to identify these branches, but do know the motor function of this nerve.**



T  
A  
S  
K

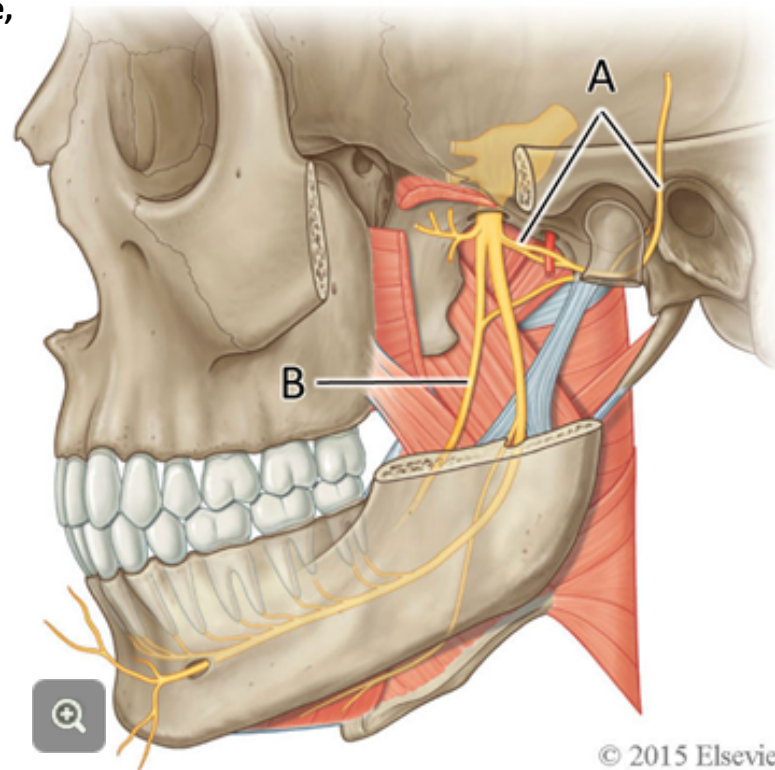
## IDENTIFY,

passing posteriorly from the foramen ovale, the **auriculotemporal branch of V<sub>3</sub>** (A).

This branch supplies sensory fibres to parts of the auricle , external auditory meatus, and external surface of the tympanic membrane .

Leaving the foramen ovale and lying anterior to the inferior alveolar nerve, identify the **lingual nerve** (B), also a branch of V<sub>3</sub>. Trace it inferiorly toward the floor of the mouth. You identified the lingual nerve in the superficial dissection of the infratemporal fossa.

The lingual nerve is sensory for the general senses of pain, touch, pressure, and temperature in the anterior 2/3 of the tongue.



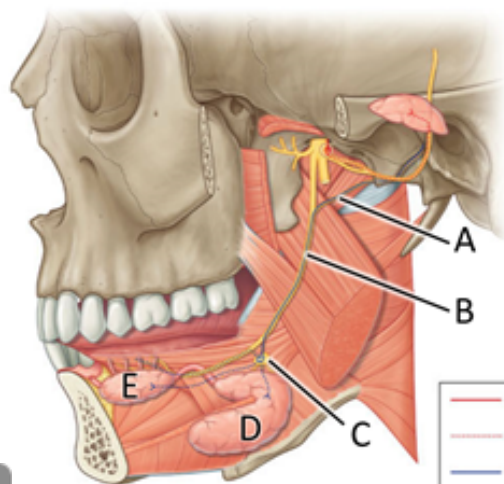




T  
A  
S  
K

**IDENTIFY** the **chorda tympani (A)** joining the **lingual nerve (B)**.

The chorda tympani is a branch of the **facial nerve, CN VII**. It carries **parasympathetic preganglionic fibres**. Once the chorda tympani unites with the lingual nerve, **the lingual nerve carries these parasympathetic preganglionic fibres to the floor of the mouth**. There they enter the **submandibular ganglion (C)**, where they synapse onto postganglionic parasympathetic neurons. **The postganglionic parasympathetic fibres are secretomotor to the submandibular (D) and sublingual (E) salivary glands, and the mucosa of the floor of the mouth, including the tongue.**



- PreG PSy fibre from IX
- PostG PSy fibres travel with the auriculotemporal N.
- PreG PSy fibre from VII
- PostG PSy fibres travel with the lingual N.

Note that this fits the pattern described in the prelab SLM on slide 4A 9 ; the **parasympathetic preganglionic fibres from CN VII** are **distributed to their target tissue by branches of the trigeminal nerve**, in this case the **lingual nerve**. **Understand this pattern; it helps you to remember the paths of parasympathetic outflow, regardless of which cranial nerve it originates from, III, VII or IX.**

The chorda tympani branches from the facial nerve during its course through the temporal bone and it leaves the skull through a tiny opening just posterior to the mandibular fossa.



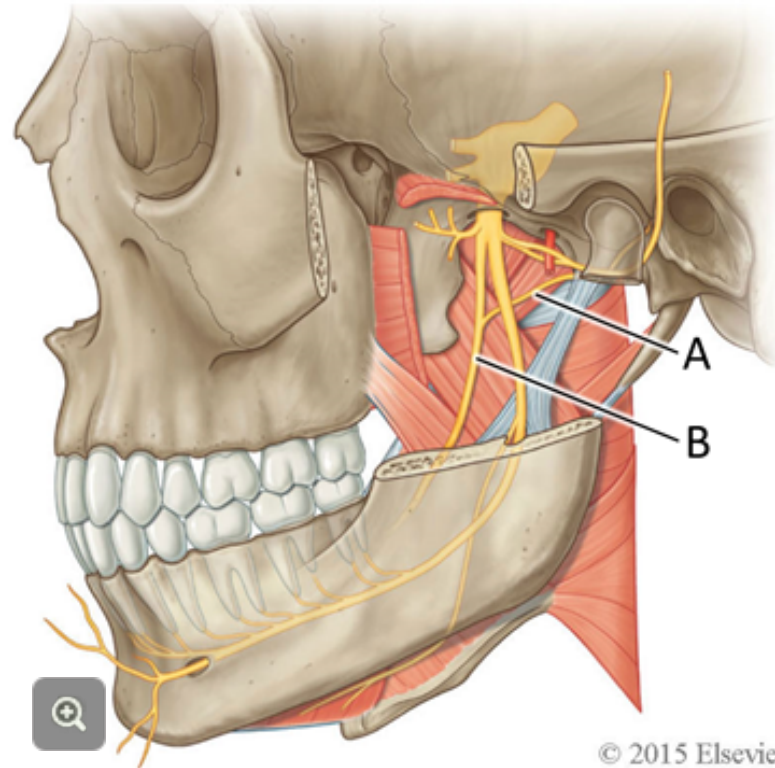
## 4.3 The Chorda Tympani Carries Taste Fibres



In addition to parasympathetic preganglionic fibres, the **chorda tympani** (A) also carries special sensory fibres for **taste to the anterior 2/3 of the tongue**.

Like the parasympathetic preganglionic fibres, the taste fibres in the chorda tympani join the **lingual nerve** (B) to enter the floor of the mouth. There they distributed to the anterior 2/3 of the tongue.

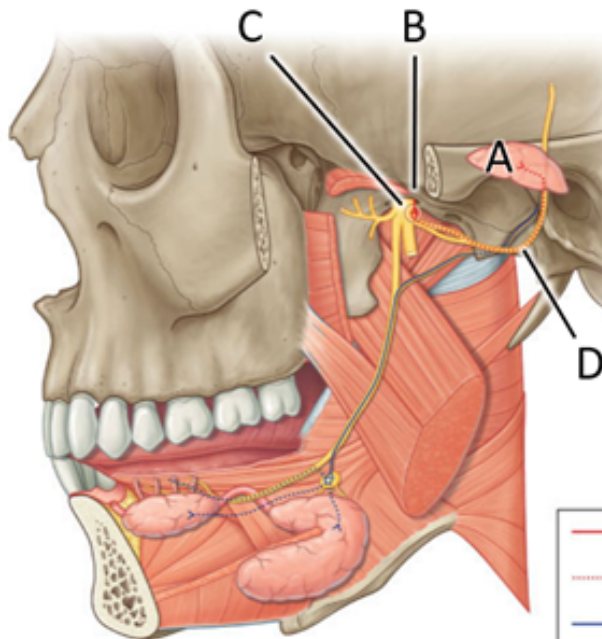
Note that the taste fibres from VII are distributed to their target tissues by the same branch of the trigeminal nerve, the lingual nerve, as are the parasympathetic fibres.




### 4.3 The PSy Innervation of the Parotid Gland Comes from CN IX







This graphic also describes the **parasympathetic innervation of the parotid gland (A)**. For this salivary gland, the preganglionic parasympathetic fibres originate in the **glossopharyngeal nerve, CN IX (B)**. Following a synapse in the **otic ganglion (C)**, the parasympathetic postganglionic fibres join the **auriculotemporal nerve (D)**, a branch of the **mandibular division of the trigeminal nerve**, to travel to the **parotid gland**.



Note that this, again, fits the pattern described in the prelab SLM on slide 4A 9 ; the **parasympathetic preganglionic fibres from CN IX** are **distributed to their target tissue by branches of the trigeminal nerve**, in this case the **auriculotemporal nerve**.

**You can see how this pattern helps you to remember the paths of parasympathetic outflow, regardless of which cranial nerve it originates from, III, VII or IX**

-  PreG PSy fibre from IX
-  PostG PSy fibres travel with the auriculotemporal N.
-  PreG PSy fibre from VII
-  PostG PSy fibres travel with the lingual N.





### TASK IN THE PROSECTION, IDENTIFY

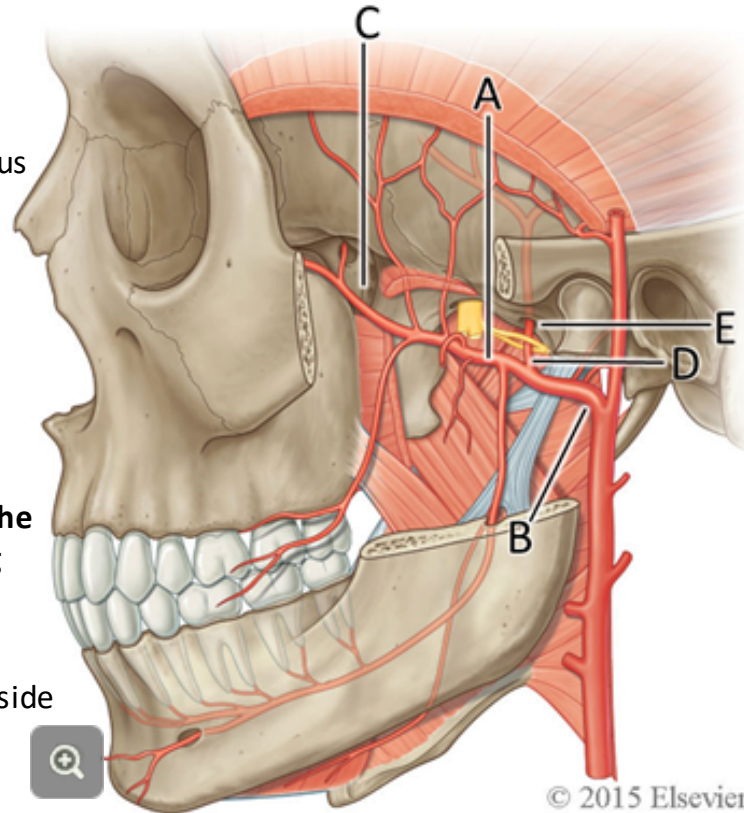
the **maxillary artery (A)** and trace it from its origin on the **external carotid artery (B)** to where it enters into the **pterygopalatine fossa** by passing through the **pterygomaxillary fissure (C)**.

From the **pterygopalatine fossa**, and through its various foramina, branches of the maxillary artery extend:

- **medially into the nasal cavity,**
- **anteriorly into the orbit,** and
- **inferiorly into the palate and upper teeth.**

Identify the **middle meningeal branch (D)** of the maxillary artery and trace it superiorly to where it disappears through the **foramen spinosum (E)** into the cranial cavity to supply the membranes surrounding the brain, the meninges.

In many specimens, and as illustrated here, the auriculotemporal nerve splits to pass around on either side of the middle meningeal artery, similar to the way that University Avenue splits to pass around the provincial parliament buildings.



Since embarking on this exercise, you have **identified** the following structures and / or learned their significance. In the case of foramina, state what passes through each. In the case of muscles, state their action and innervation. In the case of nerves and arteries, describe their distribution.

- on the bony skull: the borders of the infratemporal fossa: the ramus of the mandible, the lateral plate of the pterygoid process, the inferior surface of the neurocranium, the posterior surface of the maxillary bone, the foramen ovale, spinosum and mandibular foramen, pterygomaxillary fissure and pterygopalatine fossa
- in the superficial / deep prosection of the infratemporal fossa, as appropriate, identify the buccinator muscle, medial and lateral pterygoid muscles
- external carotid artery, maxillary artery, superficial temporal artery
- follow the maxillary artery through the infratemporal fossa and pterygomaxillary fissure into the pterygopalatine fossa; identify its branches, the inferior alveolar and middle meningeal artery, and describe their distribution. Where does the maxillary artery end? Where do its branches go from here?
- inferior alveolar nerve, mental nerve, lingual nerve, auriculotemporal nerve, chorda tympani
- describe the distribution of parasympathetic and taste fibres to structures in the floor of the mouth via branches of VII and V3
- describe the distribution of parasympathetic fibres to the parotid gland via branches of IX and V3.

If you are satisfied with your **ability to identify these structures** and **answer these questions**, call your TA over for confirmation and for **permission to move on** to the next stage of the exercise.